



Review

Pott's puffy tumor: overview of case series

Luiz Severo Bem Junior¹  Márcia Noelle Cavalcante Medeiros²  Luan de Sá Pinto Nóbrega Gadelha² 
Wagner José Raia Neri²  Marie Anne Gomes Cavalcanti² 

¹Universidade Federal de Pernambuco, Recife, Brazil

²Faculdade de Ciências Médicas - Unifacisa, Campina Grande, Brazil



Luiz Severo Bem Júnior
luizseverobemjunior@gmail.com

Edited by

Marcelo Moraes Valença

Keywords:

Pott's puffy tumor
Pott puffy tumor
Osteomyelitis
Sinusitis

Abstract

Pott's puffy tumor (PPT) is rare and usually seen as a complication of frontal sinusitis that has been neglected or partially treated, resulting in subperiosteal abscess of the frontal bone with underlying osteomyelitis, which can lead to life-threatening intracranial complications, such as epidural/subdural empyema, cerebral abscess and meningitis. Given this, the purpose of the study was to gather the most diverse cases reported together to highlight the treatment options.

Methods: This is a narrative review, starting from the search in the database PubMed, Lilacs and Scielo from 2010 to 2020. The search focused on obtaining data on new approaches and treatments established for Pott's puffy tumor.

Results: 34 articles were included which described 58 patients with a swollen Pott tumor, occurring predominantly in male adolescents, with streptococci (26.1%) as the main etiologic agent. Approximately 84% of all patients were male subjects. The most prevalent intracranial complication was an epidural or extradural abscess (84.2%). Regarding PTT therapy, all patients received antibiotic (ATB) therapy, and the main empirical antimicrobial scheme used was third generation cephalosporin, with vancomycin and metronidazole. In most cases, surgery was performed using several techniques, mainly an external surgical approach, external drainage (ED) of the subperiosteal abscess associated with endoscopic sinus surgery (ESS). In general, the prognosis was favorable, even if neurological symptoms were present at admission.

Conclusion: Based on available literature, PPT is a profoundly serious complication, which can be easily avoided if treated with the ATB, ED and ESS triad immediately, and, if necessary, craniotomy.

Received: February 25, 2021
Accepted: May 15, 2021

Introduction

In the late 18th century, Percival Pott defined a soft subperiosteal abscess of the frontal bone related to forehead trauma and associated with underlying osteomyelitis that he called "puffy tumor." The Pott's puffy tumor (PPT) may result often from a slow and gradual progression of a rare complication of frontal sinusitis or trauma to the frontal bone and skull, characterized by subperiosteal abscess with osteomyelitis.¹ The most common symptoms are headache, periorbital edema, fever, vomiting, periorbital swelling, fever, lethargy, purulent rhinorrhea, and signs of meningitis or encephalitis.^{2,3} It can be found in all ages, but there is a higher incidence among adolescents.⁴

PPT is a risk factor for intracranial complications (epidural abscess^{5,7}, subdural abscess, acute meningitis, and frontal lobe abscess), which have been found in about 60-85% of patients with PPT and may be life threatening, leading to devastating neurological ramifications. This complication is most frequently associated with long-term, untreated, or improperly treated frontal sinusitis. Besides, craniofacial traumas, surgery in the frontal region, a progressive thrombophlebitis without bone inflammation, intranasal cocaine abuse, and the several chronic diseases that affect the innate immune response, such as diabetes, chronic renal failure and aplastic anemia are also potential causes of Pott's puffy tumor.⁸

Although rare, PPT represents an important morbidity rate with neurological involvement in 30% to 40% of all cases of PPT and may include motor deficit, aphasia, cranial nerve palsy, seizures, visual deficit, intracranial hypertension, obtundation, and coma.¹ The vast majority of patients treated appropriately recover without long-term neurological complications and sequelae.^{9,10} Given this, the study aims at reviewing the literature with a focus on new approaches and treatment of this disease over the last ten years, making correlations between articles.

Material and methods

Some steps were taken to produce this narrative review article: such as establishing the question and objectives of the review; the eligibility criteria; results analysis; discussion and presentation of results, and the final step was the production of this article.

A narrative review was carried out based on the following research question: what are the new approaches, and treatment for PPT? This question was formulated by PICOS strategy, where the "P" of population is patient with Pott's Puffy Tumor, the "I" of intervention is collect information about treatments

and approaches for Pott's Puffy Tumor, the "C" of comparison is not applicable, the "O" of outcome is show the most effective treatments and approaches for Pott's Puffy Tumor, and the "S" of study design is an narrative review. From that question, the keywords were selected and organized, in the PubMed database, using the MeSh terms: (Pott's Puffy Tumor OR Pott Puffy Tumor) AND (sinusitis AND osteomyelitis).

During the research, were Filters applied which describe some inclusion criteria: Abstract, in the last 10 years, Humans, English, Spanish. Thus, we selected case reports and case series with full text availability in electronic support.

Subsequently, the search for scientific articles published in the PubMed, Lilacs, and Scielo database was carried out, based on the last research carried out on December 6, 2020, using the tool "PubMed Advanced Search Builder", to perform a more specific search, the terms "AND" and "OR" were used between the descriptors in the "Builder" tool, on the other platforms we use the same descriptors. A total of fifty-one articles were found in this expansive search across multiple platforms. Of this total, only one article refers to the expansive search, forty-one articles were identified on the PubMed and ten were secondary references in this platform. Eighteen articles were excluded because of not meeting the inclusion criteria. Of the thirty-four selected, four articles were a case series, and the rest were case reports. The search strategy is described in the PRISMA below, as the Figure 1 shows.

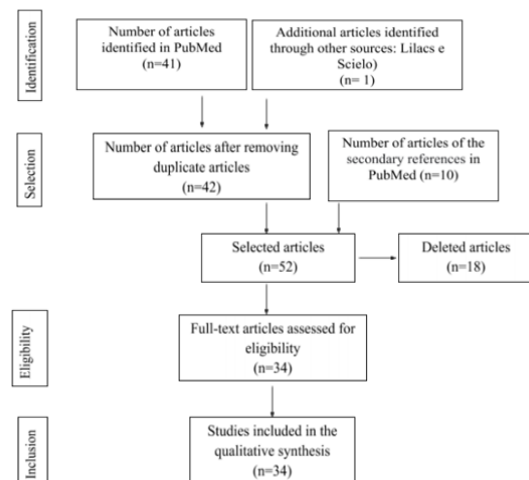


Figure 1 - Flowchart of the article selection process based on the eligibility criteria of the strategy PRISMA.

Results

Analyzing the studies included in this review, we focused on obtaining data on new approaches and treatments established for PPT, as reported in Table 1. We included 34 articles that described 58 patients with Pott's puffy tumor, occurring predominantly in adolescents, affecting the age group from 12 to 15 years more, accompanied by the pediatric age group. Of the affected patients, approximately 84% were male subjects. The main etiological agents most involved with PTT were *Streptococci* (26.1%), *Fusobacterium* (19.0%), *Staphylococcus spp.* (16.6%).

Of the 34 clinical cases studied 55.8% evolved with intracranial complication. The most prevalent intracranial complication was epidural abscess (84.2%), followed by subdural abscess (15.8%), that were diagnosed, by most authors, using computerized tomography images. In relation to treatment, all patients received antibiotic therapy, and the main empirical antimicrobial scheme used was cephalosporin third generation, vancomycin, and metronidazole. In general, the articles included in this research used an external surgical approach, mainly the external drainage of the subperiosteal abscess associated with endoscopic sinus surgery. The success of the treatments applied was in 100% of the cases. Figure 2 shows among all the cases analyzed in this systematic review, the value for each type of treatment instituted.

Table 1. Characterization of publications according to author, year, methodological design, and conclusion

Author and Year	Methods	Intracranial Complication	Infectious agent	Antibiotic therapy sequence	Conclusion
Simonin et al. ⁷	Case Report	Epidural abscess	<i>Streptococcus Intermedius</i>	Ceftriaxone	Aggressive treatment with intravenous antibiotics and surgical debridement is recommended for a patient with a history of frontal sinusitis associated with progressive forehead swelling. May lead to diagnosis.
Peric et al. 2017 ⁸	Case Report	Epidural abscess	<i>Staphylococcus aureus</i> and <i>Peptostreptococcus prevoti</i>	Ceftriaxone, metronidazole, amoxicillin-clavulanate	The lesion may propagate intracranially, resulting in dangerous intracranial inflammatory lesions. Early diagnosis, medication and surgical therapy are particularly important in reducing morbidity and mortality.
Avcu et al. ²	Case Report	There was no evidence of intracranial involvement.	Without abscess culture	Ceftriaxone, Vancomycin and metronidazole -> Amoxicillin clavulanic	The early diagnosis and treatment of PPT are emphasized, given that it may lead to serious complications, and this should be kept in mind when treating patients with a history of trauma and sinusitis who present with headache, fever and swelling in the frontal region.
Salomão et al. ¹	Case Series	A bifrontal small-sized epidural empyema.	(2) Group A beta-hemolytic streptococci (1) <i>Staphylococcus aureus</i> (3) Without abscess culture	Intravenous broad-spectrum antibiotics	The goals of PPT management are the treatment of sinusitis with broad-spectrum antibiotic agents, drainage of the subperiosteal abscess, and removal of the compromised bone. If present intracranial complication should be also promptly treated, reducing morbidity and mortality.
Haider et al. ¹¹	Case Report	Meningitis with subdural right temporal-parietal empyema.	<i>Fusobacterium necrophorum</i>	Cefuroxime -> meropenem and fosfomicine -> Meropenem, vancomycin, and ceftriaxone -> Meropenem and metronidazole	The neurosurgical drainage of the subdural empyema as well as the drainage of the subperiosteal abscess, combined with appropriate antibiotic therapy, led to a nearly complete recovery.
Sabatiello et al. ⁹	Case Report	Subdural abscess, and intracranial abscess.	<i>Peptostreptococcus</i> , <i>Fusobacterium necrophorum</i>	Amoxicillin-clavulanate -> Cefotaxime and clindamycine	Treatment consists of surgical drainage of the abscess and a long-term culture-directed intravenous and oral antibiotics course to prevent further purulent complications.
Laguna et al. ⁴	Case Report	Right epidural abscess, with purulent left frontal collection in space subarachnoid.	<i>Streptococcus pyogenes</i>	Cefotaxima and clindamicina -> Ciprofloxacino	Concluded that a fast diagnosis of PPT and an aggressive treatment with antibiotic agents are essential to reduce the risk of neurological complications.
Acke et al. ¹²	Case Report	There was no evidence of intracranial involvement.	Without abscess culture	Not described	In the failure to respond to antibiotics, surgical intervention is the treatment of choice, including drainage of the abscess and removal of the osteomyelitic bone. Postoperatively, the patient should be given appropriate antibiotic medication for a period of 6 to 8 weeks.
Patel et al. ¹³	Case Report	There was no evidence of intracranial involvement.	Without abscess culture	Ceftriaxone, vancomycin, and metronidazole-> Amoxicillin/clavulanate	Barosinusitis can be associated with potentially dangerous intracranial complications, early recognition, diagnosis, and appropriate treatment are of vital importance to reduce morbidity and mortality.
Casado Pellejero et al. ¹⁴	Case Report	Epidural abscess, and subdural abscess.	<i>Propionibacterium acnes</i> , <i>Actinomyces sp</i> and <i>Fusobacterium nucleatum</i>	Vancomicina, ceftazidima and metronidazol -> Amoxicilina	Early surgery and starting intravenous antibiotic therapy early are effective curative treatments, avoiding the spread of infection.
Rehman et al. ¹⁵	Case Report	There was no evidence of intracranial involvement.	Without abscess culture	Intravenous broad-spectrum antibiotics	A Pott puffy tumor, although exceedingly rare, may still occasionally be seen. Prompt diagnosis and proper treatment will decrease the morbidity and mortality associated with this rare condition.
Suwan et al. ¹⁶	Case Report	Epidural abscess.	<i>Streptococcus constellatus</i> , <i>Fusobacterium necrophorum</i>	Cefdinir, vancomycin, cefotaxime, and metronidazole -> Ampicillin sulbactam -> Intravenous meropenem	Prompt surgical and medical treatments are the rule, essential in achieving an ideal result, as there is the potential for significant morbidity if not quickly diagnosed and treated.

Joo et al. ¹⁷	Case Report	There was no evidence of intracranial involvement.	Without abscess culture	Ceftrizine -> Ampicillin/sulbactam -> Amoxicillin/clavulanate	Pott's puffy tumor is best diagnosed with computerized tomography (CT) and treated with early broad-spectrum antibiotics and surgical approach to prevent morbidity and mortality.
Grewal et al. ¹⁸	Case Report	There was no evidence of intracranial involvement.	<i>Eubacterium species and Coagulase negative Staphylococci</i>	Vancomycin, ceftazidime, and metronidazole -> Clindamycin	Pott's puffy tumor is an extremely serious complication which can be easily prevented by adequate and appropriate treatment of acute bacterial sinusitis currently.
Sharma et al. ³	Case Report	Epidural abscess.	<i>Streptococcus intermedius</i>	Not described	Early diagnosis and treatment are required for Pott's Puffy Tumor. Broad-spectrum antibiotics for 4 to 6 weeks, along with surgical drainage, is the standard of treatment.
Jung et al. ¹⁹	Case Report	There was no evidence of intracranial involvement.	<i>Staphylococcus aureus</i>	Ceftriaxone	Once the diagnosis is suspected, appropriate imaging should be performed to evaluate the possible complications and combine medical and surgical approaches.
Lauria et al. ²⁰	Case Report	There was no evidence of intracranial involvement.	<i>Streptococcus constellatus</i>	Amoxicillin-clavulanate -> Metronidazole, vancomycin, and ceftazidime -> Ampicillin-sulbactam	Early diagnosis of Pott puffy tumor and aggressive medical and surgical approach are essential for a good outcome.
Podolsky-Gondim et al. ²¹	Case Report	Epidural abscess.	<i>Peptostreptococcus species</i>	Ceftriaxone, oxacillin, and metronidazole -> Amoxicillin with clavulanic	Early clinical suspicion, diagnosis, and the treatment of the frontal sinusitis and its complications with surgery and broad-spectrum intravenous antibiotics bring up the possibility of good recovery, with prognosis is favorable
R. Escudero Esteban et al. ²²	Case Report	Right and left frontal epidural abscesses.	<i>Streptococo intermedius</i>	Penicillin	Epidural abscesses were evacuated and after surgery, they were treated for 6 weeks with penicillin. Partially treated frontal sinusitis can lead to this potentially dangerous complication. Proper diagnosis and treatment improve outcomes in these patients
Shahzeb Hassan et al. ²³	Case Report	Tiny epidural collection with associated Dural thickening.	<i>Fusobacterium nucleatum</i>	Vancomycin and ampicillin-sulbactam -> Ceftriaxone and metronidazole	This type of patient with an orbital fracture and hematoma can be initially evaluated and managed by an ophthalmologist. Although these are generally rare and serious cases, immediate evaluation with a multidisciplinary approach can generate promising results.
Antonio Pansini, et al. ²⁴	Case Report	There was no evidence of intracranial involvement.	<i>Staphylococcus aureus</i>	Amoxicillin-clavulanic	Combined medical and surgical treatment is the gold standard in managing PTT. Antibiotic therapy should be done with broad-spectrum antibiotics and then be based on microbiological examination. Surgery must be radical, an open and combined endoscopic approach is usually necessary and must restore the patency of the sinus ostium.
Blumfield E, Misra M ²⁵	Case Series	Epidural abscess (four cases out of five)	Without abscess culture	Not described	A high index of suspicion is needed, the use of image methods is crucial and a multidisciplinary team is imperative.
Parida PK et al. ¹⁰	Case Series.	There was no evidence of intracranial involvement.	Three cases reported sterile cultures, meanwhile one case reported MRSA and another one reported <i>Pseudomonas aeruginosa</i>	Ceftriaxone, crystalline penicillin, metronidazole, vancomycin and ceftazidime were used without a clear antibiotic therapy sequence.	Early treatment results in favorable outcomes and decreases the risk of further complications.
Burak Olmaz et al. ⁵	Case Report	Epidural abscess extension.	Without abscess culture	Amoxicillin cavulanate -> Ceftriaxone -> Vancomycin, metronidazole and Ceftriaxone	The imaging role in PPT's diagnosis and intracranial complication detection is crucial
Sekine R et al. ⁶	Case Report.	Epidural abscess.	<i>Stenotrophomonas maltophilia, Achromobacter xylosoxidans, and Corynebacterium spp.</i>	Vancomycin -> Levofloxacin	Antibiotics and surgical approach are both vital therapies in PTT cases
Bannon PD, Mccomarck RF ²⁶	Case Report.	There was no evidence of intracranial involvement	<i>Streptococcus intermedius</i>	Ampicillin/Sulbactam -> amoxicillin/clavulanate potassium -> vancomycin, ceftriaxone and metronidazole -> ceftriaxone and metronidazole	Intravenous antibiotics and surgery are important steps in PTT treatment.
Ciobanu AM et al. ²⁷	Case Report	There was no evidence of intracranial involvement	<i>Mycoplasma</i>	Doxycycline	PPT began to be reported more frequently in recent years.
Zhang SY, Deng HH ²⁸	Case Report	There was no evidence of intracranial involvement	<i>Klebsilla pneumoniae</i>	Not described	PPT is a pathology that is difficult to diagnose and requires great clinical accuracy.
Palabiyik FB et al. ²⁹	Case Series	Epidural abscess (two cases)	<i>Staphylococcus epidermidis</i> (one case), <i>E. coli</i> (one case), Sterile (four cases)	Ampicillin/sulbactam and metronidazole or ceftriaxone -> and then changed according to the results of the pus culture.	Confirm the association of PPT and intracranial complications
Şimşek H ³⁰	Case Report	There was no evidence of intracranial involvement	<i>Pseudomonas aeruginosa</i>	Ceftriaxone and metronidazole -> ciprofloxacin	In the surgical approach, it's important to remove osteomyelitic bone extended to the healthy margins.
Clarós P, Ahmed H, Clarós A. ³¹	Case report	There was no evidence of intracranial involvement	Bacteriological culture of the aspiration sample remained sterile.	Ciprofloxacin	As in the case reported here, culture can remain sterile. Miloundja et al. reported 50% of sterile culture results, reflecting preoperative use of empirical intravenous antibiotics, which sterilizes the site of infection.

Linton S, Pearman A, Joganathan V, Karagama Y. ³²	Case report	There was no evidence of intracranial involvement	Without abscess culture	Coamoxiclav and metronidazole	Intracranial and intraorbital collections require urgent surgical drainage along with combined sinus trephination.
Sheth SP, Ilkanich P, Congeni B. ³³	Cases report	Case 1 - Subdural abscess; Case 2 - There was no evidence of intracranial involvement Case 3 - Epidural abscess	Case 1 e 2 - <i>Fusobacterium necrophorum</i> , Case 3 - <i>F. necrophorum</i> , <i>F. streptococci</i> and <i>Streptococcus constellatus</i>	Case 1 - Empiric vancomycin, ceftriaxone and piperacillina, tazobactam; Case 2 - Vancomycin, clindamycin and ceftriaxone; Case 3 - Amoxicillin-clavulanic acid, levofloxacin and vancomycin	The pathogens seen do not reflect the etiology of sinusitis in general.
Shin JW et al. ³⁴	Case report	Epidural abscess	<i>Staphylococcus aureus</i> and coagulase-negative	Third generation of cephalosporin	The PPT, known as a giant frontal mucocele, is an uncommon disease entity and more rarely reported with its frontocutaneous fistula

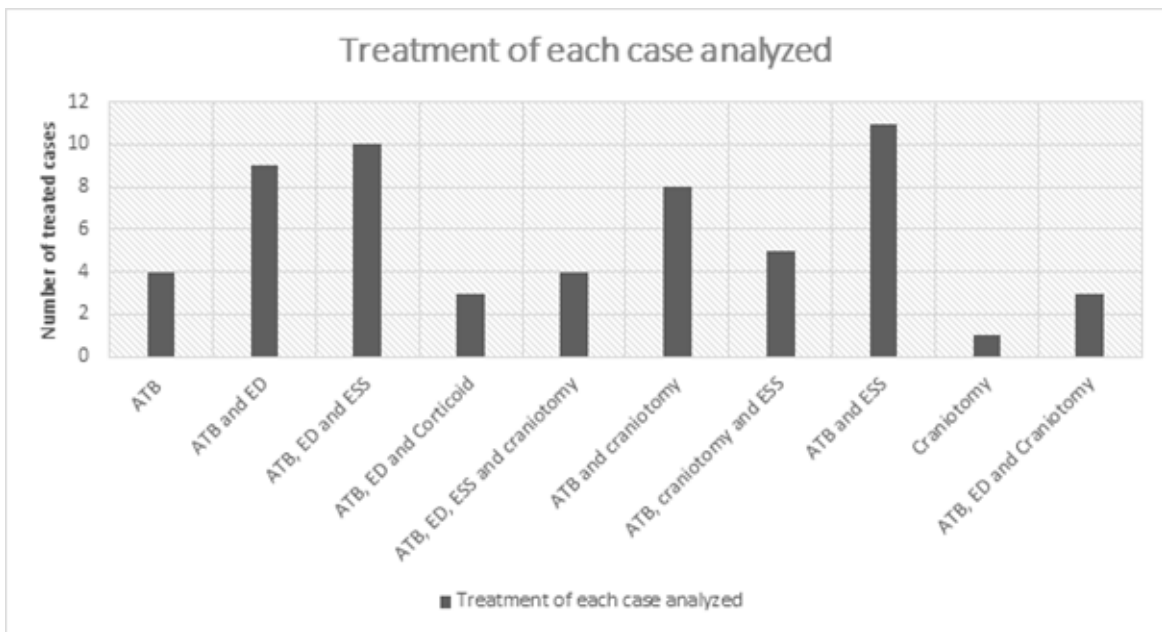


Figure 1. Treatment of each case analyzed. ATB= antibiotic therapy; ED = external drainage; ESS = endoscopic sinus surgery.

Discussion

Pott's puffy tumor consists of a subperiosteal abscess with osteomyelitis of the frontal bone.⁹ PTT is commonly related as a complication of a frontal or ethmoidal sinusitis, acute or chronic, but can see cases related after front bone trauma^{11,12,29}, and even barotrauma can be associated.¹³ PPT is a disease with low incidence and with few cases reported; this can be explained nowadays due to the widespread use of antibiotics.²⁹

The prevalence of PTT is higher among teenagers, because the venous drainage by diploic veins flow is increased during this stage of life, and can spread the infection easier,⁴ other possible causes of this epidemiology is an anatomical characteristic, like late complete aeration of the frontal sinus^{3,8,13,14}, which are often pneumatized by 2 years of age and are approximate adult size by the late teens.³ But adults can be

affected by the PTT, although rare, according to the world English-language literature, only 30-40 cases of adult patients with PPT were reported between 1990 and 2016.⁸

The bacterial agents most often involved with PPT are *Streptococci* (*Streptococcus milleri*, *Streptococcus viridians*, *Streptococcus pyogenes* e *Streptococcus pneumoniae*), *Staphylococcus aureus*, and some anaerobic bacteria (*Bacteroides* and *Fusobacterium*^{14,20,26,33}, *Mycoplasma*²⁷, *Klebsiella pneumoniae*²⁸ and *Pseudomonas aeruginosa*³⁰). These agents are the most common ones found in acute bacterial rhinosinusitis; an important fact is that most infections are caused by more than one etiologic agent.³⁵ This infectious agent propagating through mucosal venous drainage of the frontal sinus occurs through the diploic veins, which communicate with the Dural venous plexus or directly by erosion of the frontal sinus wall.^{3,14,15} However, there is a possibility that the microbial study of purulent secretion may be uncontaminated, Clarós et al.³¹ reported 50% of sterile culture results, reflecting proper-

ative use of empirical intravenous antibiotics, which sterilizes the site of infection.

It is necessary to understand the PPT itself as a complication of an initial bacterial colonization, so that there will be the formation of an intense inflammatory process and symptoms associated with both this inflammation and the topography of the PPT. The presentation of the patient will occur with local edema, headache, and fever in its entirety, and may also present cutaneous fistulations³⁴, lowering the level of consciousness and hemodynamic instability.^{1,19}

One of the main factors involved in the etiology of PPT is osteomyelitis of the frontal bone, which presupposes the occurrence of complications that affect intracranial content by extension, with data in literature that supports an uncertain risk, which varies from approximately 30%¹⁶ to 80%¹. The main reported complication is epidural abscess. Other complications reported in literature are subdural abscess, cerebral abscess and meningitis, these complications require a differentiated and individualized approach that are not the focus of this study.

Despite the non-observed relation between the risk-factors and PPT, correct and early diagnosis is important to avoid the occurrence of intracranial complication, being an important risk-factor itself.

In the event of suspecting PPT, the diagnosis should be performed early. A CT scan with intravenous contrast enhancement includes adequate information on the intracranial as well as extracranial complications of frontal sinusitis but is mostly superior to an MRI in visualization of the bone.^{3,19,21} However, MRI after an intravenous gadolinium injection showed more detail in the description of the extent of the disease and enables better evaluation of the underlying subdural space and brain. A scintigraphy evaluation can be useful in detecting and diagnosis of osteomyelitis.¹² In addition, the ultrasound forehead images can assist in the initial radiological investigation and guide the needle sampling for culture.²¹

The physiopathology of PPT made the necessity of immediate antibiotic therapy and the improvement based on the study of the pathogens clear. The antimicrobial agent used will vary according the local epidemiology, but the most prevalent drugs used long-term (not less than 8 weeks)¹⁸, according our research, are ceftriaxone, metronidazole, and vancomycin.^{1,5,29}

The surgical treatment involves logical steps but will change

depending on the complications of each case. It is necessary to make sure there will not be any material infected that could cause recurrence. The main treatment consists of a bi-coronal incision, follow by a craniotomy and drainage of purulent material, removal of infected soft tissues and debridement of the osteomyelitic focus. Furthermore, another safe procedure, a valuable technique, made to ensure the efficacy of treatment was the endoscopic approach of the anterior ethmoid cells, sometimes amplified for the maxillary sinus.^{8,14,16,21} The choice of the surgical procedure depends on the extent of the infection, as reported in Graph 1.^{14,20,22}

To increase the chances of a good prognosis, PPT should be suspected in all patients with sinusitis¹⁷, treatment must take into account the multidisciplinary approach, involving the ophthalmological vision²³, that of the otolaryngologist, maxillofacial surgeon, neurosurgeon and the anesthetist, everyone can and should contribute to the patient's favorable evolution.²⁴ In general, the prognosis is favorable, even if neurological symptoms are present upon admission, obviously, prompt diagnosis and aggressive treatment is mandatory in these cases for successful outcomes.^{19,25,32,36}

Conclusion

Therefore, the PPT has its incidence decreasing, justified by the correct use of antibiotics. However, it can be lethal if it is not diagnosed.

Furthermore, it is a very serious complication, which can be easily avoided with the appropriate treatment that includes the early use of antibiotics, with the aim of covering the associated pathogens, while the surgical approach, should always be evaluated, prioritizing the treatment triad: antibiotic therapy, external drainage and endoscopy of the affected sinuses, and, if necessary, craniotomy, which aim to reduce the damage caused by complications. Thus, the conclusions are consistent with the evidence presented.

Luiz Severo Bem Junior

<https://orcid.org/0000-0002-0835-5995>

Márcia Noelle Cavalcante Medeiros

<https://orcid.org/0000-0002-8663-6135>

Luan de Sá Pinto Nóbrega Gadelha

<http://orcid.org/0000-0002-8806-0651>

Wagner José Raia Neri

<https://orcid.org/0000-0002-4026-6271>

Marie Anne Gomes Cavalcanti

<https://orcid.org/0000-0003-0212-9679>

References

1. Salomão JF, Cervante TP, Bellas AR, Boechat MC, Pone SM, Pone MV and De APB. **Neurosurgical implications of Pott's puffy tumor in children and adolescents.** *Childs Nerv Syst* 2014;30(9):1527-1534 Doi: <https://www.doi.org/10.1007/s00381-014-2480-x>
2. Avcu G, Belet N, Kumaz SC, Karli A and Sensoy G. **Pott's puffy tumor in a 12-year-old boy.** *Pediatr Int* 2015;57(1):163-165 Doi: <https://www.doi.org/10.1111/ped.12440>
3. Sharma P, Sharma S, Gupta N, Kochar P and Kumar Y. **Pott puffy tumor.** *Proc (Bayl Univ Med Cent)* 2017;30(2):179-181 Doi: <https://www.doi.org/10.1080/08998280.2017.11929575>
4. Ainsa Laguna D, Pons Morales S, Muñoz Tormo-Figueres A, Vega Senra MI and Otero Reigada MC. **[Pott's puffy tumor: a rare complication of frontal sinusitis].** *An Pediatr (Barc)* 2014;80(5):317-320 Doi: <https://www.doi.org/10.1016/j.anpedi.2013.06.001>
5. Olmaz B, Cingoz M, Akdogan E and Kandemirli SG. **Correlation of imaging and intraoperative findings in Pott's puffy tumour.** *Scott Med J* 2019;64(1):25-29 Doi: <https://www.doi.org/10.1177/0036933018803787>
6. Sekine R, Omura K, Ishida K and Tanaka Y. **Recurrent Pott's Puffy Tumor Treated With Anterior Skull Base Resection With Reconstruction of the Anterolateral Thigh Flap.** *J Craniofac Surg* 2019;30(1):e94-e96 Doi: <https://www.doi.org/10.1097/scs.0000000000005100>
7. Simonin A, Passaplan C, Rusconi A, Colin V, Erard V, Stauffer E, . . . Otten P. **Pott's puffy tumor presenting as a frontal swelling under a Swiss army helmet.** *Clin Neurol Neurosurg* 2018;173(115-117 Doi: <https://www.doi.org/10.1016/j.clineuro.2018.06.034>
8. Perić A, Milojević M and Ivečić D. **A Pott's Puffy Tumor Associated with Epidural - Cutaneous Fistula and Epidural Abscess: Case Report.** *Balkan Med J* 2017;34(3):284-287 Doi: <https://www.doi.org/10.4274/balkanmedj.2016.1304>
9. Sabatiello M, Vanhooetghem O, Mostinckx S and De La Brassinne M. **The Pott's puffy tumor: an unusual complication of frontal sinusitis, methods for its detection.** *Pediatr Dermatol* 2010;27(4):406-408 Doi: <https://www.doi.org/10.1111/j.1525-1470.2010.01182.x>
10. Parida PK, Surianarayanan G, Ganeshan S and Saxena SK. **Pott's puffy tumor in pediatric age group: a retrospective study.** *Int J Pediatr Otorhinolaryngol* 2012;76(9):1274-1277 Doi: <https://www.doi.org/10.1016/j.ijporl.2012.05.018>
11. Haider HR, Mayatepek E, Schaper J and Vogel M. **Pott's puffy tumor: a forgotten differential diagnosis of frontal swelling of the forehead.** *J Pediatr Surg* 2012;47(10):1919-1921 Doi: <https://www.doi.org/10.1016/j.jpedsurg.2012.06.031>
12. Acke F, Lemmerling M, Heylbroeck P, De Vos G and Verstraete K. **Pott's puffy tumor: CT and MRI findings.** *Jbr-btr* 2011;94(6):343-345 Doi: <https://www.doi.org/10.5334/jbr-btr.703>
13. Patel A, Vuppula S, Hayward H, Lakhani A and Lighter J. **A Case of Pott's Puffy Tumor Associated With Barosinusitis From Scuba Diving.** *Pediatr Emerg Care* 2021;37(1):e51-e54 Doi: <https://www.doi.org/10.1097/pec.0000000000001657>
14. Casado Pellejero J, Lorente Muñoz A, Elenwoke N and Cortés Franco S. **Pott's puffy tumor by Actinomyces after minor head trauma.** *Neurocirugia (Astur : Engl Ed)* 2019;30(4):198-201 Doi: <https://www.doi.org/10.1016/j.neucir.2018.06.002>
15. Ur Rehman A, Muhammad MN and Moallam FA. **Pott puffy tumor: a rare complication of sinusitis.** *Ann Saudi Med* 2013;33(1):79-80 Doi: <https://www.doi.org/10.5144/0256-4947.2012.26.5.1116>
16. Suwan PT, Mogal S and Chaudhary S. **Pott's Puffy Tumor: An Uncommon Clinical Entity.** *Case Rep Pediatr* 2012;2012(386104 Doi: <https://www.doi.org/10.1155/2012/386104>
17. Joo MJ and Schapira KE. **Pott's Puffy Tumor: A Potentially Deadly Complication of Sinusitis.** *Cureus* 2019;11(12):e6351 Doi: <https://www.doi.org/10.7759/cureus.6351>
18. Grewal HS, Dangaych NS and Esposito A. **A tumor that is not a tumor but it sure can kill!** *Am J Case Rep* 2012;13(133-136 Doi: <https://www.doi.org/10.12659/ajcr.883236>
19. Jung J, Lee HC, Park IH and Lee HM. **Endoscopic Endonasal Treatment of a Pott's Puffy Tumor.** *Clin Exp Otorhinolaryngol* 2012;5(2):112-115 Doi: <https://www.doi.org/10.3342/ceo.2012.5.2.112>
20. Lauria RA, Laffitte Fernandes F, Brito TP, Pereira PS and Chone CT. **Extensive Frontoparietal Abscess: Complication of Frontal Sinusitis (Pott's Puffy Tumor).** *Case Rep Otolaryngol* 2014;2014(632464 Doi: <https://www.doi.org/10.1155/2014/632464>
21. Podolsky-Gondim GG, Santos MV, Carneiro VM, Pires Augusto L, Da Costa Pacheco Neto R and Santos De Oliveira R Md P. **Neurosurgical Management of Pott's Puffy Tumor in an Obese Adolescent with Asthma: Case Report with a Brief Review of the Literature.** *Cureus* 2018;10(6):e2836 Doi: <https://www.doi.org/10.7759/cureus.2836>
22. Escudero Esteban R, Pérez Piñas I and Del Estad Cabello G. **[Pott's Puffy tumor: a forgotten complication of sinusitis].** *Radiologia* 2011;53(2):175-178 Doi: <https://www.doi.org/10.1016/j.rx.2010.05.007>
23. Hassan S, Rahmani B, Rastatter JC, Jaju AI and Kurup SP. **Trauma-associated Pott's puffy tumor: an ophthalmologic perspective.** *Orbit* 2020;39(1):38-40 Doi: <https://www.doi.org/10.1080/01676830.2019.1573909>
24. Pansini A, Copelli C, Manfuso A, D'eccllesia A, Califano L and Cocchi R. **Pott's Puffy Tumor and Intranasal Cocaine Abuse.** *J Craniofac Surg* 2020;31(4):e418-e420 Doi: <https://www.doi.org/10.1097/scs.0000000000006423>

25. Blumfield E and Misra M. **Pott's puffy tumor, intracranial, and orbital complications as the initial presentation of sinusitis in healthy adolescents, a case series.** *Emerg Radiol* 2011;18(3):203-210 Doi: <https://www.doi.org/10.1007/s10140-010-0934-3>
26. Bannon PD and McCormack RF. **Pott's puffy tumor and epidural abscess arising from pansinusitis.** *J Emerg Med* 2011;41(6):616-622 Doi: <https://www.doi.org/10.1016/j.jemermed.2008.04.050>
27. Ciobanu AM, Roșca T, Vlădescu CT, Tihoan C, Popa MC, Boer MC and Cergan R. **Frontal epidural empyema (Pott's puffy tumor) associated with Mycoplasma and depression.** *Rom J Morphol Embryol* 2014;55(3 Suppl):1203-1207,
28. Zhang SY and Deng HH. **[One case of Pott's puffy tumor: inverted papilloma of nasal sinus postoperative complications].** *Lin Chung Er Bi Yan Hou Tou Jing Wai Ke Za Zhi* 2018;32(4):304-305 Doi: <https://www.doi.org/10.13201/j.issn.1001-1781.2018.04.016>
29. Palabiyik FB, Yazici Z, Cetin B, Celebi S and Hacimustafaoglu M. **Pott Puffy Tumor in Children: A Rare Emergency Clinical Entity.** *J Craniofac Surg* 2016;27(3):e313-316 Doi: <https://www.doi.org/10.1097/scs.0000000000002573>
30. Şimşek H. **Patient presenting with frontal subperiosteal abscess and headache: a case of Pott's puffy tumor.** *Br J Neurosurg* 2019;33(3):275-277 Doi: <https://www.doi.org/10.1080/02688697.2017.1330944>
31. Clarós P, Ahmed H and Clarós A. **À propos d'un cas de tumeur de Pott post-traumatique.** *Annales françaises d'Oto-rhino-laryngologie et de Pathologie Cervico-faciale* 2016;133(2):109-111 Doi: <https://doi.org/10.1016/j.anorl.2015.08.018>
32. Linton S, Pearman A, Joganathan V and Karagama Y. **Orbital abscess as a complication of Pott's puffy tumour in an adolescent male.** *BMJ Case Rep* 2019;12(7):Doi: <https://www.doi.org/10.1136/bcr-2019-229664>
33. Sheth SP, Ilkanich P and Congeni B. **Complicated Fusobacterium Sinusitis: A Case Report.** *Pediatr Infect Dis J* 2018;37(9):e246-e248 Doi: <https://www.doi.org/10.1097/inf.0000000000001927>
34. Shin JW, Choi IG, Jung SN, Kwon H, Shon WI and Moon SH. **Pott puffy tumor appearing with a frontocutaneous fistula.** *J Craniofac Surg* 2012;23(2):e158-160 Doi: <https://www.doi.org/10.1097/SCS.0b013e31824cdcc0>
35. Koltzidopoulos P, Papageorgiou E and Skoulakis C. **Pott's puffy tumor in children: A review of the literature.** *Laryngoscope* 2020;130(1):225-231 Doi: <https://www.doi.org/10.1002/lary.27757>
36. Akiyama K, Karaki M and Mori N. **Evaluation of adult Pott's puffy tumor: our five cases and 27 literature cases.** *Laryngoscope* 2012;122(11):2382-2388 Doi: <https://www.doi.org/10.1002/lary.23490>