

# Neurological complications of Covid-19: Narrative review

## *Complicações neurológicas da Covid-19: revisão narrativa*

Mateus Marinho Silva de Souza<sup>1</sup>, Matheus Araújo de Oliveira Farias<sup>1</sup>, Ana Rita de Oliveira Souza da Silva<sup>1</sup>, Nataly Regina Fonseca Carvalho de Medeiros<sup>2</sup>, Marcelo Moraes Valença<sup>1</sup>

<sup>1</sup>Núcleo de Neurologia e Neurocirurgia, Centro de Ciências Médicas, Universidade Federal de Pernambuco, Recife, Pernambuco, Brasil.

<sup>2</sup>Curso de Medicina no Centro Universitário Maurício de Nassau, Recife, Pernambuco, Brasil.

### Resumo

A pandemia causada pelo novo coronavírus trouxe consigo grandes desafios para a ciência visto sua alta taxa de transmissão, que gera uma crise nos sistemas de saúde e econômicos de todo o mundo e exige respostas rápidas por parte dos pesquisadores. Sabemos que o receptor para enzima conversora de angiotensina 2 desempenha um papel importante na infecção. Esse receptor também está presente em neurônios e células gliais do córtex motor, porção posterior do giro do cíngulo, paredes dos ventrículos, substância negra, bulbo olfatório, giro temporal médio, núcleo do trato solitário, medula ventrolateral e núcleo dorsal do vago. Motivo pelo qual o mecanismo de neuroinvasão precisa ser melhor compreendido. Suas manifestações neurológicas podem, muitas vezes, se apresentar na forma de sintomas leves, como hiposmia e ageusia. A partir de revisão da literatura, neste artigo investigamos as repercussões neurológicas da infecção pelo vírus em que foram estudadas as consequências da Covid-19 no sistema nervoso central, a resposta inflamatória causada por sua presença e o estado de hipercoagulabilidade, bem como a forma pela qual se desencadeiam as complicações, desde uma cefaleia até uma encefalopatia ou acidente vascular cerebral.

**Palavras-chave:** Coronavírus, Manifestações neurológicas, Covid-19, SARS-CoV-2.

### Abstract

The pandemic caused by the new coronavirus has brought great challenges to science, given its high transmission rate, which generates a crisis in the health and economic systems around the world and requires rapid responses from researchers. We know that the receptor for angiotensin-converting enzyme 2 plays an important role in infection. This receptor is also present in neurons and glial cells of the motor cortex, posterior portion of the cingulate gyrus, ventricles, substantia nigra, olfactory bulb, middle temporal gyrus, solitary tract nucleus, ventrolateral medulla and dorsal nucleus of the vagus. Which is why the neuroinvasion mechanism needs to be better understood. Its neurological manifestations can often present as mild symptoms, such as hyposmia and ageusia. From a literature review, in this article, we investigated the neurological repercussions of virus infection, in which the consequences of Covid-19 on the central nervous system, the inflammatory response caused by its presence and the state of hypercoagulability were studied, as well as the way complications, are triggered, from headache to encephalopathy or stroke.

**Keywords:** Coronavirus, Neurologic manifestations, Covid-19, SARS-CoV-2.

### Introduction

In late December 2019, an outbreak of pneumonia of unknown etiology affected about two-thirds of the workers at a fish market in Wuhan, China, causing its ban.<sup>1</sup> Retrospectively

accessed data, however, run back the disease inception to the beginning of the same month, when records point to the symptomatic onset of the first patient.<sup>2</sup> It was then identified that the disease was

caused by a category of coronavirus hitherto unprecedented.

In February 2020, the International Virus Taxonomy Committee announced the appointment of the new agent as severe acute respiratory syndrome coronavirus 2 (SARS-CoV-2).<sup>3</sup> Following this announcement, the World Health Organization (WHO) named the disease caused by it as coronavirus disease 2019 (Covid-19), a term that quickly became popular.<sup>3</sup> Such popularity was because, in a short period Covid-19, a previously circumscribed disease, was already spreading through several provinces of China<sup>1</sup>, reaching the point that on March 11, 2020, it would be raised to the pandemic category by WHO itself.<sup>4</sup>

Less than three months after the first infected person felt the first symptoms, evidence of neurological complications was already increasing in the scientific community.<sup>2</sup> Even more so when evidence pointed to the existence of heterogeneous neurological presentations in more than 36% of those infected.<sup>4</sup> In addition, possible neurological implications of the virus on respiratory failure found in many patients<sup>2</sup> and in neuropathological conditions, such as acute necrotizing hemorrhagic encephalitis and disseminated acute encephalomyelitis<sup>5</sup>, added special apprehension about the effects of this virus on the central nervous system and the possible neuro invasiveness.

Following this initial surveillance period, a much more comprehensive neurological picture for Covid-19 is under construction. The spectrum of neurological manifestations is varied. Starting from mild findings, such as anosmia or ageusia<sup>6</sup>, symptomatology can even reach cases of encephalopathy<sup>5</sup> or stroke<sup>7</sup> in more severe cases.

The urgency of fully understanding the neurological effects of this infection is becoming increasingly clear.<sup>8</sup> In this sense, as new evidence in this field emerges, there is a higher demand for literature reviews, which can integrate that new information into the pre-existing works. In this work, the authors reviewed the main neurological complications, bringing the state of the art in order to highlight the multiple patterns of involvement caused by Covid-19 and transform the current view of the disease, still considered by many to be an exclusive respiratory condition.

## Methods

A narrative review was made in the database Medical Literature Analysis and Retrieval System Online (MEDLINE/PubMed). The following search was made based on the MeSH descriptors and Boolean operators: “{(Covid 19) AND [(neurological manifestation) OR (neurological complication)]}”. The search period was undertaken between May 1<sup>st</sup>, 2020 and May 5, 2020.

This review included articles found in the search that was published in the last year. Of these, articles that were outside the scope of the research, *i.e.*, that did not focus on neurological complications related to Covid-19, were excluded. Additionally, works that were not written in English language, as well as files of the following types were disregarded for this work: editorials, comparative studies, comments/letters to the editor, guidelines, consensus, brief/short communications, and management protocols.

Figure 1 is based on the PRISMA tool (Preferred Reporting Items for Systematic Reviews and Meta-analyses) and summarizes the method used to search and select articles, showing the number of works related to each step of the process. The search in the database, as well as the initial selection of articles - by reading the titles - was carried out by two researchers independently (M.M.S.S. e M.A.O.F.). They were responsible for undertaking the same search and for applying the exclusion criteria. In the end, the selected articles were compared and the additions or removals of works were done in order to correct inconsistencies.

In turn, the reading of the abstracts, as well as that of the full texts, was performed by four researchers individually, but in an integrated manner, who used the aforementioned exclusion criteria.

As a result of this search, a total of 44 articles were obtained, among which 21 were review articles and 23 original articles (Figure 1), which were used as the basis for making the results and discussing this article. In addition, relevant articles or data, which might be found in the references of the texts read, were added to this work.<sup>2,3,5,8-23</sup>

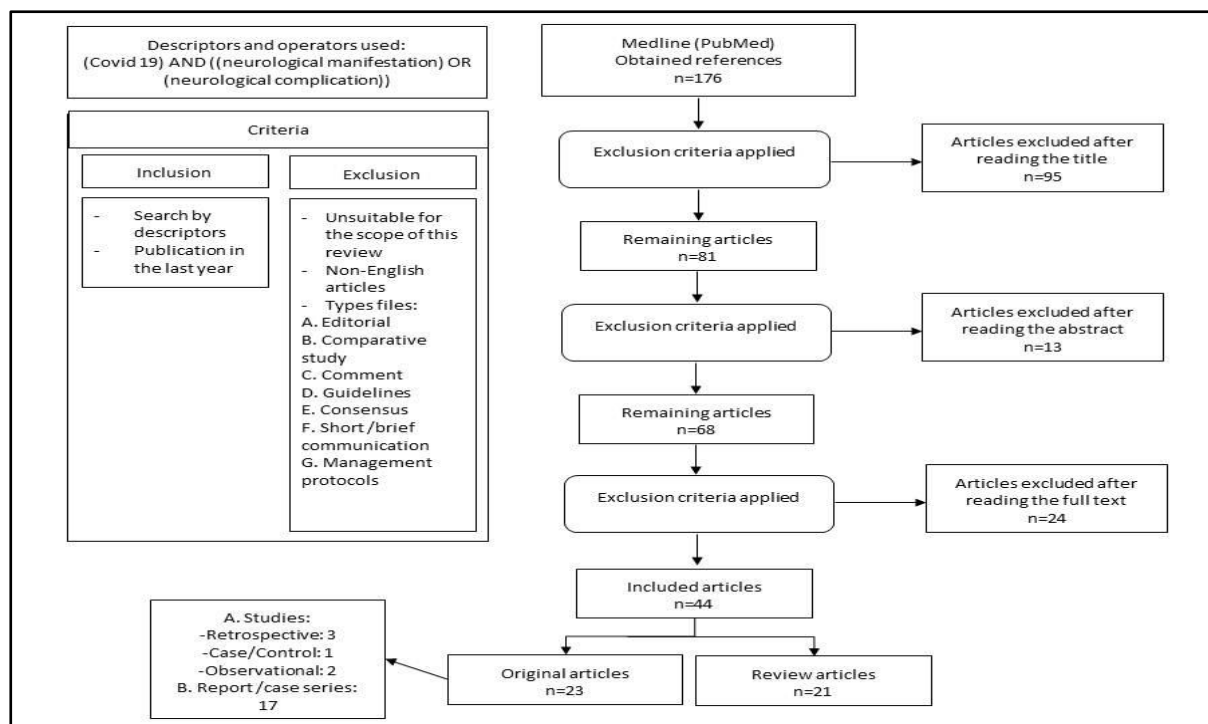


Figure 1. Article selection process

## Results and discussion

### Origin and transmission

Coronaviruses are so named due to their microscopic crown shape. As a member of the coronaviridae family, SARS-CoV-2 is related to the severe acute respiratory syndrome virus (SARS-CoV) and the Middle East respiratory syndrome virus (MERS-CoV).<sup>19,24,25</sup> The transmission of SARS-Cov-2 is done mainly by contacting the oral, nasal or conjunctival mucosa with saliva droplets or nasal secretions from infected people, whether symptomatic or asymptomatic.<sup>25</sup> Asymptomatic carriers of SARS-CoV-2, as well as those with mild symptoms, potentially contribute to the spread of the disease.<sup>25</sup> The vertical transmission of this virus is not yet well defined, however, the neonatal infection occurs due to the contact of the caregiver with contaminated surfaces.<sup>19,25</sup>

### Incubation period

The estimated average incubation period for SARS-CoV-2 is 2 to 14 days<sup>8,24,25</sup>, occurring mainly between 3 and 7 days. The understanding of the virus incubation period allows inferences about important public health activities for infectious diseases, as proposals for active monitoring,

surveillance, control, and modeling can be developed.<sup>26</sup>

### Infection stages

There are three stages of infection with SARS-CoV-2. Phase 1 has the clinic characterized by flu-like respiratory infection; phase 2 has the clinic characterized by a high risk of thrombosis, and phase 3 has the clinic represented by the critically ill patient in the intensive care unit. It was observed that patients who were at higher risk of poor disease evolution also had a higher risk score for Birmingham - 2009, which assesses the chances of thromboembolic events. These more severe patients are also more susceptible to neurological complications.<sup>20</sup>

As described, the imbalance of coagulation factors present in phase 2 may enable the formation of platelet thrombi in small vessels and this is a risk factor not only for the respiratory condition but also for neurological manifestations.<sup>20,27</sup> In this sense, it is necessary to predict or reverse the prothrombotic state of some patients using anticoagulants. D-dimer, a fibrin degradation product, is also used to assess the risk of venous thromboembolism.<sup>20,27</sup>

These degradation products are usually elevated in a serious SARS-CoV-2 infection, a

mechanism that can lead to cerebrovascular disorders, such as ischemic stroke.<sup>27</sup>

Such an inflammatory state can leave patients even more vulnerable to central nervous system complications, as lesions in the vessels also favor the attraction of coagulation factors, which in turn, favor the state of hypercoagulability.<sup>10,11</sup>

#### *Pathophysiology*

Several routes of dissemination are proposed for SARS-CoV-2 based on the admissible pathways through which respiratory viruses can reach the central nervous system, such as hematological dissemination, neuronal dissemination by retrograde transport - through the use of olfactory and trigeminal nerves, via cerebrospinal fluid or lymphatic dissemination.<sup>21</sup> Added to these findings, evidence of the possibility of infection by SARS-CoV via transnasal, with dissemination from the olfactory nerve in rodent models, suggest the same route for SARS-CoV-2, if it is considered that there is sufficient homology between these viruses.<sup>23</sup>

The viruses of the *coronaviridae* family use binding affinities between host membrane receptors and spike proteins (S) of the capsule for cell adhesion and subsequent infection.<sup>22</sup> The invasion mechanism shared by both SARS-CoV and SARS-CoV-2 is based on affinity for the human angiotensin-converting enzyme 2 (hACE2)<sup>23</sup>, through a process aided by the serine transmembrane protease 2 (TMPRSS2).<sup>22</sup> The hACE2 is a membrane protein from multiple body locations. Particularly in the brain, these receptors are expressed in the motor cortex, posterior portion of the cingulate gyrus, ventricles, substantia nigra, olfactory bulb, middle temporal gyrus, solitary tract nucleus, ventrolateral medulla, and dorsal vagus nucleus<sup>28</sup>, generating possible areas of vulnerability to the virus in the brain.

In addition, one of the possible mechanisms for neurological manifestations resides in the high immune response led by the disease<sup>24</sup>, evidenced by the finding of lymphopenia and elevation of C-reactive protein (CRP)<sup>29</sup> in part of those infected, is even more evident in patients with neurological presentations.<sup>4</sup>

Also, unusual but fatal immune complications can be described, such as cytokine storm syndromes.<sup>9</sup>

#### *Hypercoagulable state*

A recent description of complications in the severe inflammatory state due to infection with SARS-CoV-2 is associated with a considerable disturbance of hemostasis. Serological tests showed an immunological component, especially in critically ill patients.<sup>10</sup>

Also, the presence of anticardiolipin, IgA antibodies, as well as IgG and anti- $\beta$ 2-glycoprotein I antibodies have been detected. These antiphospholipid antibodies target abnormal phospholipid proteins and may temporarily increase in patients with critical illnesses and various infections, such as SARS-CoV-2 infection.<sup>10</sup>

For patients with acute cerebrovascular disease, a pro-inflammatory state triggered by cytokines can contribute to vascular endothelial damage, as well as the state of hypercoagulability that can result in extensive thrombosis and dysfunction.<sup>11</sup> Covid-19 can be a trigger for this storm of inflammatory cytokines.<sup>8</sup> As a consequence, an endothelial lesion and ischemic stroke can occur.<sup>10,27</sup> Other hemodynamic complications are deep venous thrombosis, cerebral venous sinus thrombosis, and pulmonary embolism.<sup>11</sup>

#### *Neurological complications of Covid-19*

Regarding the probable neurological complications resulting from Covid-19, there was a trend towards cerebrovascular outcomes. One of the studies carried out in a specialized neurology service showed a reduction in the number of new events of cerebrovascular events.<sup>30</sup> However, there is a proportional increase in the registration of severe cases of the disease, with occlusion of large vessels, in patients evaluated with confirmation of infection by SARS-CoV-2.<sup>30</sup> One of the possible explanations would be that in mild cases the local population avoided going to specialized services, to the detriment of more exuberant staff and due to access to services during the pandemic.<sup>30</sup>

Other studies, however, point to a probable correlation between the virus and cerebral vascular outcomes, such as ischemic or hemorrhagic stroke.<sup>4,7,30-32</sup> As so, a single-service study found that among 841 patients, 483 had neurological symptoms such as myalgia, headache, dizziness, syncope, disorders of consciousness, epilepsy,

muscle damage, myopathy, and encephalitis.<sup>33</sup> Furthermore, it is speculated that an inflammatory cascade could trigger or exacerbate neuropathic processes such as viral encephalitis, multiple sclerosis and post-Guillain-Barré Covid-19.<sup>32-37</sup> However, it is relevant to highlight that still questioned whether, in fact, the new coronavirus is involved in neurological outcomes or the incidence of these implications occurs in patients with cerebrovascular risk factors.<sup>38</sup> In addition to these findings, they stand out, especially that in initial cases such as mild clinical presentations, anosmia and dysgeusia may prevail, and may be prolonged even after resolution of the respiratory conditions.<sup>4,6,33,35,37,39-42</sup>

Neuropsychiatric involvement<sup>33</sup> is also pointed out, although it cannot be said that they would be the exclusive cause of Covid-19 or due to socioeconomic circumstances arising from the crisis due to infection by SARS-CoV-2. Therefore, the literature points to several neurological disorders that may be present in patients who have the syndrome caused by SARS-CoV-2 and the recognition of these findings can be used for a better study and delimitation of the disease.

The development of myopathies was also reported, in addition to the exacerbation of these conditions<sup>24</sup>. A retrospective study in China involving about 200 patients revealed that a subset of subjects (usually with comorbidities and the elderly) with Covid-19 had impaired consciousness, acute cerebrovascular disease, and skeletal muscle symptoms, suggesting the involvement of the central nervous system and the peripheral nervous system.<sup>24</sup> It is estimated that the latency period of the virus may be enough to destroy neurons in the medulla oblongata.<sup>8</sup>

A systematic review also showed brain complications related to SARS-CoV-2 infection: polyneuropathy, demyelinating diseases, encephalitis, and strokes.<sup>27</sup> Other neurological outcomes such as the development of Guillain-Barré syndrome after infection by this viral agent have been described (Table 1). In this way, better knowledge about the main symptoms related to these neuroaxis outcomes becomes relevant for the proper understanding, recognition, and management of cases of Covid-19.

### *Anosmia, hypogeusia and Covid-19*

Hyposmia and anosmia, decreased sense of smell, and loss of smell, respectively, and less commonly taste disorders, are reported in patients with Covid-19, even in the absence of upper airway involvement.<sup>14</sup>

It may occur initially or appears suddenly throughout the infection.<sup>14</sup> A study of 417 patients from Covid-19 from mild to moderate, 85.6% and 88% of patients, respectively, described disorders of smell and taste.<sup>15</sup> Furthermore, dysfunction olfactory was the initial symptom in 12% of cases.<sup>15</sup>

### *Guillain-Barré syndrome and Covid-19*

Despite the inconsistent onset of symptoms concerning the diagnosis of Covid-19, about the Guillain-Barré syndrome, most reports describe consistent clinical characteristics such as marked weakness of the lower limb on the upper limb, loss of deep reflexes with sensory changes, and various abnormalities.<sup>48</sup> However, the increase in cerebrospinal fluid protein has not been universal in some studies and patients with significant respiratory impairment of SARS-CoV-2, measuring vital capacity due to Guillain-Barré syndrome.

### *Cerebrovascular disease and Covid-19*

New evidence suggests that patients with Covid-19 could have neurological symptoms related to cerebrovascular diseases. Abboud and colleagues<sup>49</sup> demonstrated an important correlation between SARS-CoV-2 infection and stroke, since from 34 patients with Covid-19 evaluated, up to 6% of them had an ischemic stroke. In another study, Jain and collaborators<sup>32</sup> reaffirm the idea that these thromboembolic events are closely related to viral infection and assume neurological consequences. The authors confirmed, through neuroimaging, that 69% of patients (n=26) had neuroradiological abnormalities compatible with ischemic stroke.<sup>32</sup> The mechanisms that involve this condition include hypercoagulability with elevated D-dimer levels, exaggerated systemic inflammation and cardioembolism due to virus-related cardiac injury.<sup>8,10,11,30,49</sup>

Also, intracerebral hemorrhage has been reported in several elderly patients with Covid-19.<sup>49</sup> This is because, when binding to hACE2, SARS-CoV-2 can cause an abnormal increase in blood pressure. This hypertension, associated with the

presence of thrombocytopenia<sup>49</sup> and coagulation disorders, increases the risk of intracerebral hemorrhage in patients.<sup>49</sup> In a study, Craen and colleagues<sup>31</sup> reported subarachnoid hemorrhage in a 66-year-old woman infected with SARS-CoV-2.

Although Covid-19 is known for its respiratory symptoms, there is evidence that neurological symptoms may occur in the first 1-2 days of infection and ischemic stroke 2 weeks after the onset of the clinical symptomatic phase. The key is to prevent the patient to progress from a moderate infection into a severe infection.<sup>50</sup>

Table 2. Summary of the neurological implications

<b>Topography</b>	<b>Implications</b>
Central nervous system	Acute cerebrovascular disease <sup>4,7,30-33</sup> Ataxia <sup>4</sup> Dizziness <sup>4,33,42</sup> Encephalitis <sup>32-36</sup> Headache <sup>4,33</sup> Meningitis <sup>43</sup> Multiple sclerosis <sup>37</sup> Seizure <sup>4,33</sup>
Peripheral nervous system	Diminished sense of smell, taste <sup>4,6,33,35,37,39-42</sup> Entrapment neuropathy <sup>44</sup> Flaccid paralysis <sup>7,37,45</sup> Guillain-Barré syndrome <sup>35,37,38,46,47</sup> Nerve pain <sup>4</sup>
Muscular symptoms	Myalgia <sup>33,42</sup> Skeletal muscle injury <sup>4</sup>
Cognitive impairment	Attention and memory deficit <sup>7,36,45</sup> Impaired visual-spatial abilities <sup>4,7</sup>
Mood-altering behaviour	Anxiety <sup>33</sup> Depression <sup>33</sup>

### *Encephalopathy and Covid-19*

There are recent reports on neurological presentations of SARS-CoV-2 confirmed by computed tomography and magnetic resonance imaging of the head. The patients showed symptoms of encephalopathy, which was confirmed by imaging examination as necrotizing hemorrhagic encephalopathy. This is a rare disorder that leads to brain dysfunction caused mainly by viruses, which results in seizures, liver problems, and mental disorientation after infection.<sup>5</sup>

### *Encephalitis, Meningitis and Covid-19*

Moriguchi and collaborators<sup>16</sup> reported the first confirmed case of Covid-19 associated with viral encephalitis in Japan. A 24-year-old man presented with fever, followed by seizures and loss of consciousness, as well as stiff neck.<sup>16</sup>

Al-Olama and colleagues<sup>43</sup> reported the case of a 36-year-old man who presented drowsiness, headache, body pain, and mild confusion. Cranial tomography showed a right

frontal intracerebral hematoma associated with subarachnoid hemorrhage in the ipsilateral Sylvius fissure and the temporal and frontal lobes.<sup>43</sup> The findings were described as encephalitis, and the viral etiology was suspected. Also, abnormalities of supratentorial leptomeninges was detected, which subsequently supported the diagnosis of Covid-19 related to meningoencephalitis.<sup>17,43</sup>

## Conclusion

It is undeniable that the Covid-19 pandemic takes on a challenging issue worldwide due to its consequences acutely and chronically, either in people's health or in its economic impact. The classic respiratory symptoms are well described, but the new neurological evidence already indicates an alarming danger of the possible neuropathogenicity of the coronavirus. The most relevant issue of this probable neurotropism of the virus is that the long-term effects may result in an increased risk of neurodegenerative diseases, with involvement in the pathogenesis of neurological disorders such as Parkinson's disease or multiple sclerosis. It is also considered that the severity and progression of the neurological condition are more likely to worsen in patients with Covid-19 with pre-existing neuroaxis disorders. Therefore, more research and experimental models are of paramount importance to identify the neurological implications of Covid-19 and reduce the underreporting of this correlation.

## References

1. Wu YC, Chen CS, Chan YJ (2020) The outbreak of COVID-19: An overview. *J Chin Med Assoc.* 83(3):217-220. doi:10.1097/JCMA.0000000000000270
2. Li Z, Huang Y, Guo X (2020) The brain, another potential target organ, needs early protection from SARS-CoV-2 neuroinvasion. *Sci China Life Sci.* 63(5):771-773. doi:10.1007/s11427-020-1690-y
3. World Health Organization. Naming the coronavirus disease (COVID-19) and the virus that causes it. Published 2020. Accessed June 5, 2020. [https://www.who.int/emergencies/diseases/novel-coronavirus-2019/technical-guidance/naming-the-coronavirus-disease-\(covid-2019\)-and-the-virus-that-causes-it](https://www.who.int/emergencies/diseases/novel-coronavirus-2019/technical-guidance/naming-the-coronavirus-disease-(covid-2019)-and-the-virus-that-causes-it)
4. Mao L, Jin H, Wang M, et al. (2020) Neurologic Manifestations of Hospitalized Patients with Coronavirus Disease 2019 in Wuhan, China. *JAMA Neurol.* 77(6):683-690.

doi:10.1001/jamaneurol.2020.1127

5. Poyiadji N, Shahin G, Noujaim D, Stone M, Patel S, Griffith B. COVID-19-associated Acute Hemorrhagic Necrotizing Encephalopathy: CT and MRI Features. *Radiology.* 201187. doi:10.1148/radiol.2020201187
6. Hjelmesæth J, Skaare D (2020) Loss of smell or taste as the only symptom of COVID-19. *Tidsskr Nor Laegeforen.* 140(7). doi:10.4045/tidsskr.20.0287
7. Morassi M, Bagatto D, Cobelli M, et al. Stroke in patients with SARS-CoV-2 infection: case series. *J Neurol.* Published online May 2020:1-8. doi:10.1007/s00415-020-09885-2
8. Das G, Mukherjee N, Ghosh S (2020) Neurological Insights of COVID-19 Pandemic. *ACS Chem Neurosci.* 11(9):1206-1209. doi:10.1021/acscchemneuro.0c00201
9. Mehta P, McAuley DF, Brown M, Sanchez E, Tattersall RS, Manson JJ (2020) COVID-19: consider cytokine storm syndromes and immunosuppression. *Lancet (London, England).* 395(10229):1033-1034. doi:10.1016/S0140-6736(20)30628-0
10. Zhang Y, Xiao M, Zhang S, et al. (2020) Coagulopathy and antiphospholipid antibodies in patients with covid-19. *N Engl J Med.* 382(17):E38. doi:10.1056/NEJMc2007575
11. Thachil J (2020) The versatile heparin in COVID-19. *J Thromb Haemost.* (April):1020-1022. doi:10.1111/jth.14821
12. Panigada M, Bottino N, Tagliabue P, et al. (2020) Hypercoagulability of COVID-19 patients in Intensive Care Unit. A Report of Thromboelastography Findings and other Parameters of Hemostasis. *J Thromb Haemost.* 00:1-5. doi:10.1111/jth.14850
13. Carod-Artal FJ (2020) Neurological complications of coronavirus and COVID-19. *Rev Neurol.* 70(9):311-322. doi:10.33588/RN.7009.2020179
14. Giacomelli A, Pezzati L, Conti F, et al. (2020) Self-reported Olfactory and Taste Disorders in Patients With Severe Acute Respiratory Coronavirus 2 Infection: A Cross-sectional Study. *Clin Infect Dis.* doi:10.1093/cid/ciaa330
15. Lechien JR, Chiesa-Estomba CM, De Siati DR, et al. (2020) Olfactory and gustatory dysfunctions as a clinical presentation of mild-to-moderate forms of the coronavirus disease (COVID-19): a multicenter European study. *Eur Arch oto-rhino-laryngology Off J Eur Fed Oto-Rhino-Laryngological Soc Affil with Ger Soc Oto-Rhino-Laryngology - Head Neck Surg.* 6:1-11. doi:10.1007/s00405-020-05965-1
16. Moriguchi T, Harii N, Goto J, et al. (2020) A first case of meningitis/encephalitis associated with SARS-

Coronavirus-2. *Int J Infect Dis.* 94:55-58. doi:10.1016/j.ijid.2020.03.062

17. Ahmad I, Rathore FA (2020) Neurological manifestations and complications of COVID-19: A literature review. *J Clin Neurosci Off J Neurosurg Soc Australas.* 77:8-12. doi:10.1016/j.jocn.2020.05.017

18. Li YC, Bai WZ, Hashikawa T (2020) The neuroinvasive potential of SARS-CoV2 may play a role in the respiratory failure of COVID-19 patients. *J Med Virol.* 92(6):552-555. doi:10.1002/jmv.25728

19. Lauer SA, Grantz KH, Bi Q, et al. (2020) The incubation period of coronavirus disease 2019 (CoVID-19) from publicly reported confirmed cases: Estimation and application. *Ann Intern Med.* 172(9):577-582. doi:10.7326/M20-0504

20. Reis PEO, Lima MCB, Reis PEO, Lima MCB (2020) Podemos atuar preventivamente para evitar que os pacientes portadores de COVID-19 evoluam de forma mais grave? *J Vasc Bras.* 19:3-5. doi:10.1590/1677-5449.200057

21. Desforges M, Le Coupanec A, Dubeau P, et al. (2019) Human Coronaviruses and Other Respiratory Viruses: Underestimated Opportunistic Pathogens of the Central Nervous System? *Viruses.* 12(1). doi:10.3390/v12010014

22. Hoffmann M, Kleine-Weber H, Schroeder S, et al. (2020) SARS-CoV-2 Cell Entry Depends on ACE2 and TMPRSS2 and Is Blocked by a Clinically Proven Protease Inhibitor. *Cell.* 181(2):271-280.e8. doi:10.1016/j.cell.2020.02.052

23. Netland J, Meyerholz DK, Moore S, Cassell M, Perlman S (2008) Severe acute respiratory syndrome coronavirus infection causes neuronal death in the absence of encephalitis in mice transgenic for human ACE2. *J Virol.* 82(15):7264-7275. doi:10.1128/JVI.00737-08

24. Ng Kee Kwong KC, Mehta PR, Shukla G, Mehta AR (2020) COVID-19, SARS and MERS: A neurological perspective. *J Clin Neurosci.* 77:13-16. doi:10.1016/j.jocn.2020.04.124

25. Singhal T (2020) A Review of Coronavirus Disease-2019 (COVID-19). *Indian J Pediatr.* 87(4):281-286. doi:10.1007/s12098-020-03263-6

26. Rudler AH, Denneval C, Herson P, Nie X, Fan L, Mu G, et al. (2020) Epidemiological characteristics and incubation period of 7,015 confirmed cases with Coronavirus Disease 2019 outside Hubei Province in China. *J Infect Dis.* 222(1):26-33. doi:10.1093/infdis/jiaa211

27. Montalvan V, Lee J, Bueso T, De Toledo J, Rivas K (2020) Neurological manifestations of COVID-19 and

other coronavirus infections: A systematic review. *Clin Neurol Neurosurg.* 194:105921. doi:10.1016/j.clineuro.2020.105921

28. Zubair AS, McAlpine LS, Gardin T, Farhadian S, Kuruvilla DE, Spudich S (2020) Neuropathogenesis and Neurologic Manifestations of the Coronaviruses in the Age of Coronavirus Disease 2019: A Review. *JAMA Neurol.* doi:10.1001/jamaneurol.2020.2065

29. Cheng Q, Yang Y, Gao J (2020) Infectivity of human coronavirus in the brain. *EBioMedicine.* 56:102799. doi:10.1016/j.ebiom.2020.102799

30. Siegler JE, Heslin ME, Thau L, Smith A, Jovin TG (2020) Falling stroke rates during COVID-19 pandemic at a Comprehensive Stroke Center: Cover title: Falling stroke rates during COVID-19. *J stroke Cerebrovasc Dis Off J Natl Stroke Assoc.* 29(8):104953. doi:10.1016/j.jstrokecerebrovasdis.2020.104953

31. Craen A, Logan G, Ganti L (2020) Novel Coronavirus Disease 2019 and Subarachnoid Hemorrhage: A Case Report. *Cureus.* 12(4):e7846. doi:10.7759/cureus.7846

32. Jain R, Young M, Dogra S, et al. (2020) COVID-19 related neuroimaging findings: A signal of thromboembolic complications and a strong prognostic marker of poor patient outcome. *J Neurol Sci.* 414:116923. doi:10.1016/j.jns.2020.116923

33. Romero-Sánchez CM, Díaz-Maroto I, Fernández-Díaz E, et al. (2020) Neurologic manifestations in hospitalized patients with COVID-19: The ALBACOVID registry. *Neurology.* doi:10.1212/WNL.00000000000009937

34. Filatov A, Sharma P, Hindi F, Espinosa PS (2020) Neurological Complications of Coronavirus Disease (COVID-19): Encephalopathy. *Cureus.* 12(3):e7352. doi:10.7759/cureus.7352

35. Andrea A, Luana B, Silvia DM, Erika S, Massimo DS (2020) New clinical manifestation of COVID-19 related Guillain-Barrè syndrome highly responsive to intravenous immunoglobulins: two Italian cases. *Neurol Sci Off J Ital Neurol Soc Ital Soc Clin Neurophysiol.* doi:10.1007/s10072-020-04484-5

36. Haddadi K, Ghasemian R, Shafizad M (2020) Basal Ganglia Involvement and Altered Mental Status: A Unique Neurological Manifestation of Coronavirus Disease 2019. *Cureus.* 12(4):e7869. doi:10.7759/cureus.7869

37. Goh Y, Beh DLL, Makmur A, Somani J, Chan ACY (2020) Pearls and Oysters: Facial nerve palsy as a neurological manifestation of Covid-19 infection. *Neurology.* doi:10.1212/WNL.00000000000009863

38. Ottaviani D, Boso F, Tranquillini E, et al. (2020) Early Guillain-Barré syndrome in coronavirus disease 2019 (COVID-19): a case report from an Italian COVID-hospital. *Neurol Sci Off J Ital Neurol Soc Ital Soc Clin Neurophysiol.* 41(6):1351-1354. doi:10.1007/s10072-020-04449-8
39. Beltrán-Corbellini Á, Chico-García JL, Martínez-Poles J, et al. (2020) Acute-onset smell and taste disorders in the context of COVID-19: a pilot multicentre polymerase chain reaction based case-control study. *Eur J Neurol.* 0:1-4. doi:10.1111/ene.14273
40. Hopkins C, Surda P, Whitehead E, Kumar BN (2020) Early recovery following new onset anosmia during the COVID-19 pandemic - an observational cohort study. *J Otolaryngol - head neck Surg = Le J d'oto-rhino-laryngologie Chir cervico-faciale.* 49(1):26. doi:10.1186/s40463-020-00423-8
41. Melley LE, Bress E, Polan E (2020) Hypogeusia as the initial presenting symptom of COVID-19. *BMJ Case Rep.* 13(5). doi:10.1136/bcr-2020-236080
42. Zanin L, Saraceno G, Panciani PP, et al. (2020) SARS-CoV-2 can induce brain and spine demyelinating lesions. *Acta Neurochir (Wien).* 162(7):1491-1494. doi:10.1007/s00701-020-04374-x
43. Al-Olama M, Rashid A, Garozzo D (2020) COVID-19-associated meningoencephalitis complicated with intracranial hemorrhage: a case report. *Acta Neurochir (Wien).* 162(7):1495-1499. doi:10.1007/s00701-020-04402-w
44. Righi G, Del Popolo G (2020) COVID-19 tsunami: the first case of a spinal cord injury patient in Italy. *Spinal cord Ser cases.* 6(1):22. doi:10.1038/s41394-020-0274-9
45. Avula A, Nalleballe K, Narula N, et al. (2020) COVID-19 presenting as stroke. *Brain Behav Immun.* 87: 115–119. doi: 10.1016/j.bbi.2020.04.077
46. Juliao Caamaño DS, Alonso Beato R (2020) Facial diplegia, a possible atypical variant of Guillain-Barré Syndrome as a rare neurological complication of SARS-CoV-2. *J Clin Neurosci Off J Neurosurg Soc Australas.* 77:230-232. doi:10.1016/j.jocn.2020.05.016
47. Lascano AM, Epiney J-B, Coen M, et al. (2020) SARS-CoV-2 and Guillain-Barré syndrome: AIDP variant with favorable outcome. *Eur J Neurol.* doi:10.1111/ene.14368
48. Whittaker A, Anson M, Harky A (2020) Neurological Manifestations of COVID-19: A systematic review and current update. *Acta Neurol Scand.* 142(1): 14-22. doi:10.1111/ane.13266
49. Abboud H, Abboud FZ, Kharbouch H, Arkha Y, Abbadi N El, Ouahabi A El (2020) COVID-19 and SARS-Cov-2 Infection: Pathophysiology and Clinical Effects on the Nervous System. *World Neurosurg.* 140:49-53 . doi:10.1016/j.wneu.2020.05.193
50. Zhou Y, Li W, Wang D, et al. (2020) Clinical time course of COVID-19, its neurological manifestation and some thoughts on its management. *Stroke Vasc Neurol.* 5(2):177-179. doi:10.1136/svn-2020-000398

Correspondence:  
Mateus Marinho Silva de Souza  
mateus.marinhos@ufpe.br

Received: June 10, 2020 Accepted: June 30, 2020