

▪ 2022, 4(2): ▪ e-ISSN: 2674-7103

Jornal Memorial *da* Medicina

▪ DOI: 10.37085/jmmv4.n2.2022.pp.23-28

Case report

Parietal nodular lesion on the scalp: probable renal cell carcinoma metastasis - a case report

Lesão nodular parietal em couro cabeludo: provável metástase de carcinoma de células renais - relato de caso

Joaquim Fechine de Alencar Neto[1], Rocymar Rebouças Oliveira Júnior[1], Evandil Carneiro Alves Júnior[1], Otávio da Cunha Ferreira Neto[2], Arthur Oliveira Lira[1], Luís Felipe Ferreira Marques[3], Luís Bandeira Alves Neto[4], Maria Luisa Rocha[5], Melissa Helena Rodrigues Silva[2], Herika Karla Negri Brito[6], Talita Borges Brito[1], Luiz Severo Bem Junior[1,6], Hildo Rocha Cirne de Azevedo Filho[7]

[1]College of Medical Sciences, Unifacisa University Center, Campina Grande, Paraíba, Brazil.
[2]Catholic University of Pernambuco, Recife, Pernambuco, Brazil.
[3]Mato Grosso State Univesity, Cárceres, Mato Grosso, Brazil.
[4]University of Pernambuco, Recife, Pernambuco, Brazil.
[5]Brasília University Center, Brasília, Distrito Federal, Brazil.
[6]Department of Neurosurgery, Hospital da Restauração, Recife, Pernambuco, Brazil.
[7]Neuroscience Post-Graduate Program, Federal University of Pernambuco, Recife, Pernambuco, Brazil

Joaquim Fechine de Alencar Neto
joaquimfechine.n@gmail.com.

Edited by
Marcelo Moraes Valença

Abstract

Among the renal lesions described, renal cell carcinoma (RCC) is the primary renal neoplastic tumor reaching males in a proportion two times higher than females and characterizing about 2% of the carcinomas of the adult population. Although the treatment of this type of cancer has evolved in recent years, the management of patients with metastatic conditions remains challenging, with possible spreads to the lungs and bones. Vascular metastasis of RCC to the skin, especially the scalp, is a rare condition with few reports described in the literature. The diagnosis of this lesion should consider the patient's clinic, especially in cases with a previous history of renal carcinoma, and maybe a differential diagnosis for vascular lesions. Although the treatment is surgical, there may be an association with possible adjuvant treatments.

Resumo

Dentre as lesões renais descritas, o carcinoma de células renais (CCR) é o principal tumor renal neoplásico atingindo o sexo masculino em proporção duas vezes maior que o feminino e caracterizando cerca de 2% dos carcinomas da população adulta. Embora o tratamento desse tipo de câncer tenha evoluído nos últimos anos, o manejo de pacientes com quadros metastáticos continua desafiador, com possível disseminação para pulmões e ossos. A metástase vascular de CCR para a pele, principalmente o couro cabeludo, é uma condição rara, com poucos relatos descritos na literatura. O diagnóstico dessa lesão deve levar em consideração a clínica do paciente, principalmente nos casos com história prévia de carcinoma renal, podendo ser um diagnóstico diferencial para lesões vasculares. Embora o tratamento seja cirúrgico, pode haver associação com possíveis tratamentos adjuvantes.

Keywords:
Renal metastasis
Parietal lesion
Scalp
Renal cell carcinoma

Palavras-chave:
Spine
Epidermoid cyst
Spinal cord neoplasm
Case report

Submitted: December 5, 2022
Accepted: December 22, 2022
Published: December 29, 2022

© Copyright 2022

Introduction

Renal cell carcinoma (RCC) is a malignant lesion with a 2:1 male ratio. Symptoms range from flank pain, hematuria and palpable abdominal masses. There could also be a systemic disease with secondary hypertension and hyperkalemia. Diagnosis is made essentially with imaging tests.[1] Clinical conditions such as smoking, obesity, and hypertension are risk factors for renal cell carcinoma. RCC corresponds to about 2% to 3% of malignant tumors in the adult population and is the primary lesion among kidney neoplasms.[2] Despite surgical treatment and advances in the mechanisms of interventions on RCC, the prognosis and therapy of patients with metastatic conditions remain complex, with effective responses of around 25%.[3]

Among the sites of metastasis, the main ones are the lungs, liver, and bone. The spread of this lesion to the skin remains an uncommon site, whose differential diagnosis involves expansive vascular lesions.[4] The treatment and diagnosis of this type of condition are still little described in the literature. It is a condition of complex clinical management, as it is already an advanced case of vascular metastasis of neoplastic cells.

Case report

A 58-year-old male patient, a long-time smoker, and renal cell carcinoma patient was referred by the dermatologist to the outpatient neurosurgery service after attempting to resection a right parietal nodular lesion. In the referral letter, significant tissue bleeding was reported after attempted exeresis of the tumor, and suspicion of major arterial irrigation was raised. The patient underwent an ultrasound of soft parts of the skull which evidenced a well-defined, isoechoic oval nodule with lobulated contours, associated with hypervascularization on color Doppler. Contrasted intracranial arterial and venous Magnetic Resonance Angiography revealed a solid nodular lesion centered on the right parietal subcutaneous tissue (Figure 1), with insinuations to the subgaleal planes, characterized by isosignal on T1, mild hypersignal on T2 and heterogeneous post-gadolinium enhancement, with discrete vascular "serpiginous" and "flow voids" structures amid the nodule (Figure 2). The nodule lays in close contact with the outer table of the parietal bone and measured 4.2 x 3.2 x 2.2 cm (craniocaudal x laterolateral x anteroposterior), without signs of intracranial extension. The lesion exhibited predominant arterial vascularization with branches originating from the right occipital artery and main venous drainage to the right occipital vein, with a small venous intradiploic insinuation in the occipital bone.

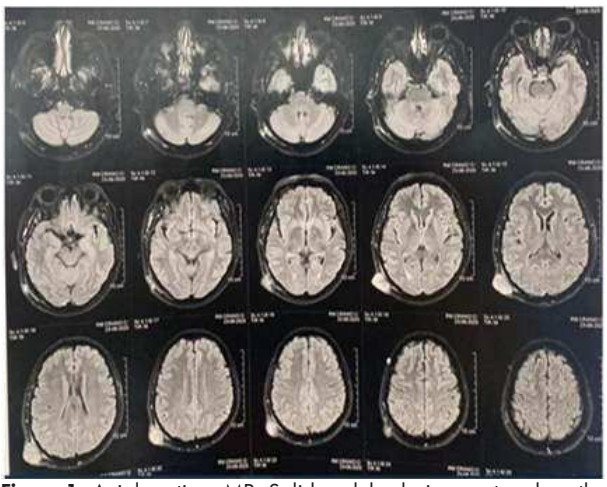

Figure 1: Axial section, MR. Solid nodular lesion centered on the right parietal subcutaneous tissue

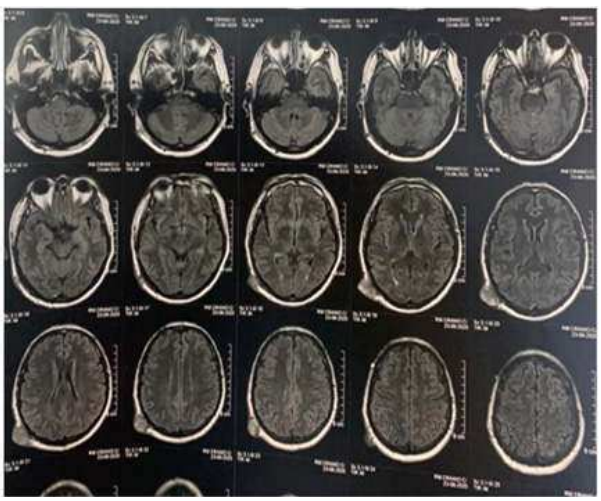

Figure 2: Axial section, MR. Discrete vascular structures inside the lesion

The hypothesis of a vascular renal cell carcinoma metastasis in the scalp, instead of a Hemangioma, raised after response to chemotherapy. The oncology outpatient unit kept the patient in close follow-up and the nodular lesion diminished, still patient keeps an irregular chemotherapy treatment for his kidney neoplasm which makes it difficult to monitor the disease, hence the necessity of neurosurgical intervention for lesion biopsy. Although a biopsy of the lesion was requested, it was not performed due to loss of patient follow-up.

Discussion

Renal Cell Carcinoma (RCC) comprises a heterogeneous

group of cancers derived from renal tubular epithelial cells[5], among which Clear cell Renal Cell Carcinoma (ccRCC) stands out, accounting for up to 80% of reported cases.[6] The detection of RCC has increased in the last decade; each year, about 271,000 new cases are diagnosed worldwide.[7] The latter is mainly due to the increased use of imaging tests that allow renal masses to be detected early and incidentally[8] and the global increase in obesity and smoking, which favor the onset of the neoplasm.[9] The patient in question, although not obese, reports being a long-time smoker.

Taking into consideration that historically, 60% of solid renal masses grow over time, the risk of these tumors becoming clinically active or evolving with metastasis is evident[10], leading to the need for early direct intervention with nephrectomy (partial or total) or ablation of the malignant tissue.[11,12] The minimally invasive approach should be prioritized to preserve renal function and avoid unnecessary surgical removal of the entire kidney.[12]

RCC metastases usually affect the lungs, liver, bones, lymph nodes, and adrenal glands[13], with bone metastasis being the most prevalent, accounting for about 1/3 of reported cases.[14] On the other hand, the metastatic cutaneous lesion is a rare entity observed in less than 3% of cases.[13] This is usually a single, bluish-red, rapidly growing, and sometimes pulsatile lesion that utilizes lymphatic and hematogenous routes to disseminate. Such lesions normally present on the face and scalp, compromising the epidermis, dermis, or hypodermis.[15-18]

Table 1: Summary of reported cases of RCC with scalp metastasis. M, male; F, female

No.	Reporter	Sex/age (yr)	Treatment to the primary tumor	Location	Treatment of metastasis	Time interval to skin metastasis (mo)
1	Haruki et al.[19]	M/67	Radical nephrectomy	Parietal	Mass excision	48
2	Williams and Heaney[20]	M/54	Radical nephrectomy	Left parietal	none	84
3	Katta[21]	M/82	none	none	Mass excision	24
4	Snow et al.[22]	F/69	Radical nephrectomy	Left posterior parietal	Mass excision	4
5	Pan et al.[23]	M/63	Radical nephrectomy	Scalp	none	none
6	Jin et al.[24]	M/73	Radical nephrectomy	Vertex	Mass excision	48
7	Rekhi et al.[25]	F/15	none	Occipital	Mass excision and palliative chemotherapy	none
8	Song et al.[26]	M/62	none	Left parietal	none	none
9	Johnson et al.[27]	F/40	Radical nephrectomy	Right frontoparietal	Mass excision	4
10	Matias et al.[28]	M/64	Radical nephrectomy	Right temporal	Mass excision	192
11	Abbasi et al.[29]	M/42	Radical nephrectomy	Scalp	Mass excision	1
12	Anzalone et al.[30]	M/58	Sunitinib	Occipital	Mass excision	36
13	Errami et al.[31]	M/64	Radical nephrectomy	Right occipitoparietal and frontal	none	36
14	Selvi et al.[32]	M/51	Radical nephrectomy	Left parietal	Mass excision	36
15	McAndrew and Ghasri[33]	M/69	Radical nephrectomy	Right occipitotemporal	none	36
16	Tjarks and Ferringer[34]	M/59	none	Left parietal	Mass excision	none
17	Georgy et al.[35]	M/63	none	Frontal and temporal	none	2
18	Badri et al.[36]	M/65	Radical nephrectomy and auxiliary chemotherapy	Left parietal	Mass excision	9
19	Zhou et al.[37]	F/85	Radical nephrectomy	Right frontoparietal	Mass excision	24
20	Kishore et al.[38]	M/58	none	Right parietal	chemotherapy and radiotherapy	2
21	Baykan and Baykan[39]	F/40	Radical nephrectomy	Occipital	Mass excision	14
22	Yang and Kang[17]	F/83	Radical nephrectomy	Right parietotemporal	Mass excision	276
23	Mann et al.[40]	M/51	none	Left scalp	Mass excision	2
24	Krogerus et al.[41]	M/65	Partial nephrectomy	Right occipital	Mass excision	9
25	Balawender et al.[42]	M/68	Radical nephrectomy	none	Mass excision	54
26	Leve et al.[43]	M/75	Radical nephrectomy	Right parietal	Mass excision	84
27	Singla et al.[44]	M/53	Partial nephrectomy and Sunitinib	Right frontoparietal	Mass excision	18

Once the skin metastasis is detected, before establishing the therapeutic scheme, it is necessary to search for other sites of involvement, considering that skin metastasis is usually late in the disease and therefore is a marker of poor prognosis.[45] Treatment of metastatic stage RCC will depend heavily on the overall status of the patient and the degree of metastasis extension. However, there is a subset of slow-growing metastasis for which active surveillance (AS) should be pursued over systemic therapy (TS), saving the toxicity of treatment, increasing life expectancy, and safely preserving patients' quality of life.46 It should be noted that there is a remote possibility of complete natural regression of the tumor in 0.3%-0-8% of cases (Cuckow and Doyle, 1991); however, once skin metastasis is diagnosed, the estimated average patient survival is 7 to 32 months.[20,47]

Conclusion

The report presents the case of a male patient with a probable metastatic RCC lesion in the right parietal scalp. Unfortunately, due to the difficulty in the patient's follow-up and poor access to oncological treatment, surgical indication for excision of the lesion and biopsy was not performed. Due to previous lesion regression in response to initial chemotherapy treatment, there is a high probability of vascular metastasis of renal neoplasia, a rare condition poorly described in the literature. The report of this type of case helps to describe this condition better and facilitates decision-making in patients with similar presentations. Nevertheless, further studies and descriptions are needed to offer these patients the best treatment and management.

Joaquim Fechine de Alencar Neto
https://orcid.org/0000-0003-2042-4874
Rocymar Rebouças Oliveira Júnior
https://orcid.org/0000-0002-7845-3435
Evandil Carneiro Alves Júnior
https://orcid.org/0000-0002-9744-9378
Otávio da Cunha Ferreira Neto
https://orcid.org/0000-0003-0517-0212
Arthur Oliveira Lira
https://orcid.org/0000-0002-5746-5728
Luís Felipe Ferreira Marques
https://orcid.org/0000-0001-7461-8637
Luis Bandeira Alves Neto
https://orcid.org/0000-0003-3245-1036
Maria Luísa Rocha
https://orcid.org/0000-0001-8717-2363
Melissa Helena Rodrigues Silva
https://orcid.org/0000-0001-9846-3801
Herika Karla Negri Brito
https://orcid.org/0000-0002-9644-8947
Talita Borges Brito
Luiz Severo Bem Junior
https://orcid.org/0000-0002-0835-5995
Hildo Rocha Cirne de Azevedo Filho
https://orcid.org/0000-0002-1555-3578

Conflict of interest

The authors declare that they have no known competing financial interests or personal relationships that could have appeared to influence the work reported in this paper.

Funding

This article has not received any kind of financial support.

Authors contribution

JFAN, methodology, investigation, writing-original draft; RROJ, ECAJ, OCFN, AOL, LFFM, LBAN, MLR, MHRS, HRCAF, data curation, writing-original draft, investigation, formal analysis, resource, writing-review & editing; JFAN, LSBJ, TBB, HRCAF, conceptualization, validation, formal analysis, resources, project administration, supervision.

References

1. Rini BI, Campbell SC and Escudier B. **Renal cell carcinoma.** *Lancet* 2009;373(9669):1119-1132 Doi:10.1016/s0140-6736(09)60229-4
2. Gupta K, Miller JD, Li JZ, Russell MW and Charbonneau C. **Epidemiologic and socioeconomic burden of metastatic renal cell carcinoma (mRCC): a literature review.** *Cancer Treat Rev* 2008;34(3):193-205 Doi:10.1016/j.ctrv.2007.12.001
3. Lam JS, Leppert JT, Belldegrun AS and Figlin RA. **Novel approaches in the therapy of metastatic renal cell carcinoma.** *World J Urol* 2005;23(3):202-212 Doi:10.1007/s00345-004-0466-0
4. Paula TA, Silva PS and Berriel LG. **Renal cell carcinoma with cutaneous metastasis: case report.** *J Bras Nefrol* 2010;32(2):213-215
5. Chan TY. **World Health Organization classification of tumours: Pathology & genetics of tumours of the urinary system and male genital organs.** *Urology* 2005;65:214-215 Doi:10.1016/j.urology.2004.09.048
6. Qi X, Li Q, Che X, Wang Q and Wu G. **The Uniqueness of Clear Cell Renal Cell Carcinoma: Summary of the Process and Abnormality of Glucose Metabolism and Lipid Metabolism in ccRCC.** *Front Oncol* 2021;11:727778 Doi:10.3389/fonc.2021.727778
7. Ferlay J, Shin HR, Bray F, Forman D, Mathers C and Parkin DM. **Estimates of worldwide burden of cancer in 2008: GLOBOCAN 2008.** *Int J Cancer*

2010;127(12):2893-2917 Doi:10.1002/ijc.25516
8. Zagoria RJ. **Imaging of small renal masses: a medical success story.** *AJR Am J Roentgenol* 2000;175(4):945-955 Doi:10.2214/ajr.175.4.1750945
9. Lipworth L, Tarone RE and McLaughlin JK. **The epidemiology of renal cell carcinoma.** *J Urol* 2006;176(6 Pt 1):2353-2358 Doi:10.1016/j.juro.2006.07.130
10. Abouassaly R, Lane BR and Novick AC. **Active surveillance of renal masses in elderly patients.** *J Urol* 2008;180(2):505-508; discussion 508-509 Doi:10.1016/j.juro.2008.04.033
11. El Dib R, Touma NJ and Kapoor A. **Cryoablation vs radiofrequency ablation for the treatment of renal cell carcinoma: a meta-analysis of case series studies.** *BJU Int* 2012;110(4):510-516 Doi:10.1111/j.1464-410X.2011.10885.x
12. Ljungberg B, Bensalah K, Canfield S, Dabestani S, Hofmann F, Hora M, . . . Bex A. **EAU guidelines on renal cell carcinoma: 2014 update.** *Eur Urol* 2015;67(5):913-924 Doi:10.1016/j.eururo.2015.01.005
13. Bujons A, Pascual X, Martínez R, Rodríguez O, Palou J and Villavicencio H. **Cutaneous metastases in renal cell carcinoma.** *Urol Int* 2008;80(1):111-112 Doi:10.1159/000111742
14. Bianchi M, Sun M, Jeldres C, Shariat SF, Trinh QD, Briganti A, . . . Karakiewicz PI. **Distribution of metastatic sites in renal cell carcinoma: a population-based analysis.** *Ann Oncol* 2012;23(4):973-980 Doi:10.1093/annonc/mdr362
15. Alcaraz I, Cerroni L, Rütten A, Kutzner H and Requena L. **Cutaneous metastases from internal malignancies: a clinicopathologic and immunohistochemical review.** *Am J Dermatopathol* 2012;34(4):347-393 Doi:10.1097/DAD.0b013e31823069cf
16. Arrabal-Polo MA, Arias-Santiago SA, Aneiros-Fernandez J, Burkhardt-Perez P, Arrabal-Martin M and Naranjo-Sintes R. **Cutaneous metastases in renal cell carcinoma: a case report.** *Cases J* 2009;2:7948 Doi:10.4076/1757-1626-2-7948
17. Barbagelata López A, Ruibal Moldes M, Blanco Díez A, Fernández Rosado E, Ponce Díaz-Reixa JL, Novas Castro S, . . . González Martín M. **Cutaneous metastasis of a renal carcinoma: case report and review.** *Arch Esp Urol* 2005;58(3):247-250 Doi:10.4321/s0004-06142005000300011
18. Dorairajan LN, Hemal AK, Aron M, Rajeev TP, Nair M, Seth A, . . . Gupta NP. **Cutaneous metastases in renal cell carcinoma.** *Urol Int* 1999;63(3):164-167 Doi:10.1159/000030440
19. Haruki T, Takahashi S, Morohashi M, Maruyama T and Ida M. **Cutaneous metastasis of renal cell carcinoma: an electron microscopic study.** *J Dermatol* 1991;18(4):218-224 Doi:10.1111/j.1346-8138.1991.tb03071.x
20. Williams JC and Heaney JA. **Metastatic renal cell carcinoma presenting as a skin nodule: case report and review of the literature.** *J Urol* 1994;152(6 Pt 1):2094-2095 Doi:10.1016/s0022-5347(17)32319-4
21. Katta R. **What's causing these scalp nodules? Cutaneous metastasis.** *Postgrad Med* 2000;108(4):115-116 Doi:10.3810/pgm.2000.09.15.1246
22. Snow S, Madjar D, Reizner G, Mac KE and Bentz M. **Renal cell carcinoma metastatic to the scalp: case report and review of the literature.** *Dermatol Surg* 2001;27(2):192-194 Doi:10.1046/j.1524-4725.2001.00115.x
23. Pan D, Niall O, Sharma H and Gya D. **Isolated scalp nodule in patient with undiagnosed RCC.** *ScientificWorldJournal* 2006;6:2430-2432 Doi:10.1100/tsw.2007.377
24. Jin WW, Chung JM, Jung KE, Park JW and Kim MH. **A Case of Metastatic Renal Cell Carcinoma Mimicking Granuloma Pyogenicum.** *Ann Dermatol* 2008;20(4):263-266 Doi:10.5021/ad.2008.20.4.263
25. Rekhi B, Kumar R, Menon S, Medhi S and Desai SB. **Calvarial metastasis of a renal cell carcinoma, mimicking a primary alveolar soft part sarcoma, in a young girl-a rare case report.** *Pathol Oncol Res* 2009;15(1):137-141 Doi:10.1007/s12253-008-9097-x
26. Song IC, Lim JS, Yun HJ, Kim S, Kang DY and Lee HJ. **Biochemical and pathological response of prostate cancer in a patient with metastatic renal cell carcinoma on sunitinib treatment.** *Jpn J Clin Oncol* 2009;39(12):833-836 Doi:10.1093/jjco/hyp110
27. Johnson RP, Krauland K, Owens NM and Peckham S. **Renal medullary carcinoma metastatic to the scalp.** *Am J Dermatopathol* 2011;33(1):e11-13 Doi:10.1097/DAD.0b013e3181e4b4eb
28. Matias M, Casa-Nova M, Borges-Costa J and Ribeiro L. **Unusual head metastasis of kidney cancer.** *BMJ Case Rep* 2013;2013:bcr2013200004 Doi:10.1136/bcr-2013-200004
29. Abbasi F, Alizadeh M, Noroozinia F and Moradi A. **Cutaneous metastasis of bilateral renal cell carcinoma.** *J Pak Med Assoc* 2013;63(1):111-113
30. Anzalone CL, Cohen PR, Migden MR and Tannir NM. **Mohs surgery in metastatic cancer: renal cell carcinoma solitary cutaneous metastasis and visceral tumor metastases to skin treated with microscopically controlled surgical excision.** *Int J Dermatol*

2013;52(7):856-861 Doi:10.1111/ijd.12021
31. Errami M, Margulis V and Huerta S. **Renal Cell Carcinoma Metastatic to the Scalp.** *Rare Tumors* 2016;8(4):6400 Doi:10.4081/rt.2016.6400
32. Selvi F, Faquin WC, Michaelson MD and August M. **Three Synchronous Atypical Metastases of Clear Cell Renal Carcinoma to the Maxillary Gingiva, Scalp and the Distal Phalanx of the Fifth Digit: A Case Report.** *J Oral Maxillofac Surg* 2016;74(6):1281-1289 Doi:10.1016/j.joms.2016.01.054
33. McAndrew R and Ghasri P. **Firm pink nodule on the scalp.** *Cutis* 2016;98(6):376;383;384
34. Tjarks BJ and Ferringer TC. **Red-blue nodule on the scalp.** *Cutis* 2017;99(1):15;25;26
35. Georgy JT, Mathuram AJ, George AA and Chandramohan J. **Renal cell carcinoma presenting as a cutaneous horn and nodules on the gingiva and scalp.** *BMJ Case Rep* 2017;2017:bcr2017220913 Doi:10.1136/bcr-2017-220913
36. Badri M, Gader G, Bahri K and Zammel I. **Skull metastasis revealing a renal tumor: A case report and review of the literature.** *Int J Surg Case Rep* 2018;43:56-60 Doi:10.1016/j.ijscr.2018.01.025
37. Zhou MH, Dunn GP, Osbun JW, Cross DT, 3rd, Moran CJ, Dacey RG, Jr. and Kansagra AP. **Direct puncture Onyx embolization of a large calvarial metastasis with intracranial extension: Case report.** *Interv Neuroradiol* 2018;24(2):220-224 Doi:10.1177/1591019917740353
38. Kishore M, Chauhan DS and Dogra S. **Unusual presentation of renal cell carcinoma: A rare case report.** *J Lab Physicians* 2018;10(2):241-244 Doi:10.4103/jlp.Jlp_153_17
39. Ferhatoglu MF, Senol K and Filiz AI. **Skin Metastasis of Renal Cell Carcinoma: A Case Report.** *Cureus* 2018;10(11):e3614 Doi:10.7759/cureus.3614
40. Mann J, Wernham A, Kulkarni K and Varma S. **An unexpected lesion on the scalp.** *Clin Exp Dermatol* 2020;45(7):922-924 Doi:10.1111/ced.14268
41. Krogerus C, Svenning M, Pilt AP and Trøstrup H. **Renal cell carcinoma presenting as a tumor on the scalp: A case report.** *Int J Surg Case Rep* 2020;76:56-59 Doi:10.1016/j.ijscr.2020.09.122
42. Balawender K, Przybyła R, Orkisz S, Wawrzyniak A, Boroñ D and Grabarek BO. **Cutaneous metastasis as the first sign of renal cell carcinoma - crossroad between literature analysis and own observations.** *Postepy Dermatol Alergol* 2022;39(3):553-558 Doi:10.5114/ada.2021.108275
43. Leve PP, Felício J, Carneiro R and Zagalo C. **Recurrent renal cell carcinoma presenting as a cutaneous metastasis: A case report and review of the literature.** *Urol Ann* 2021;13(2):174-176 Doi:10.4103/ua.Ua_2_20
44. Singla A, Sharma U, Makkar A, Masood PF, Goel HK, Sood R, . . . Singh R. **Rare metastatic sites of renal cell carcinoma: a case series.** *Pan Afr Med J* 2022;42:26 Doi:10.11604/pamj.2022.42.26.33578
45. Jindal T, Sinha RK, Mukherjee S and Karmakar D. **Calvarial and cutaneous metastasis as the primary presentation of a renal cell carcinoma.** *BMJ Case Rep* 2014;2014: bcr2013202830 Doi:10.1136/bcr-2013-202830
46. Harrison MR, Costello BA, Bhavsar NA, Vaishampayan U, Pal SK, Zakharia Y, . . . George DJ. **Active surveillance of metastatic renal cell carcinoma: Results from a prospective observational study (MaRCC).** *Cancer* 2021;127(13):2204-2212 Doi:10.1002/cncr.33494
47. Koga S, Tsuda S, Nishikido M, Matsuya F, Saito Y and Kanetake H. **Renal cell carcinoma metastatic to the skin.** *Anticancer Res* 2000;20(3b):1939-1940