

▪ 2021, 3(1):23-25 ▪ e-ISSN: 2674-7103

Jornal Memorial *da* Medicina

▪ DOI: 10.37085/jmmv3.n1.2021.pp.23-25

Image in Medicine

Radiological aspects of idiopathic lumbosacral plexitis

Artêmio José Araruna Dias[1] Júlio César Tavares Marques[1] Luís Felipe Gonçalves de Lima[1] Nilson Batista Lemos[1] Andrey Maia Silva Diniz[2] Otávio da Cunha Ferreira Neto[3] Keyvid dos Santos Pereira[4] Hildo Rocha Cirne de Azevedo Filho[4,5] Luiz Severo Bem Junior[4,5]

[1] UNIFACISA, Campina Grande, Brazil
[2] Federal University of Paraiba, João Pessoa, Brazil
[3] Catholic University of Pernambuco, Recife, Brazil
[4] Department of Neurosurgery, Hospital da Restauração, Recife, Brazil
[5] Neuroscience Post-Graduate Program, Federal University of Pernambuco, Recife, Brazil

Artêmio José Araruna Dias
ararunadias@gmail.com

Edited by
Juliana Ramos Andrade

Keywords:
Lumbosacral plexopathy
non-diabetic lumbosacral radiculo-plexus neuropathy
autoimmune demyelination

Abstract

Idiopathic Lumbosacral Plexitis is a disease that does not have definitive causes but even starts to be studied by Sander Evans et al. in 1981 hypotheses were forward related to viral infections, vaccines and heterologous serum. Although more recently, studies have showed that the disease can develop without immunological history. Multiple roots and nerves can be affected, and it can be bilateral. The differential diagnosis of other pathologies must involve research for tumors, traumas, and diabetes. The findings of the disease include: autoimmune demyelination and vasculitis with axonal lesion. The clinical condition is characterized by intensive pain, paresis, hypoesthesia in lower members, and a limping gait. The prognosis is positive; however do not have a complete remission without squeals. The treatment has not been defined but is common to uses corticosteroids and immunoglobulin.

Received: June 27, 2021
Accepted: July 27, 2021

© Copyright 2021

Introduction

Idiopathic lumbosacral plexitis (ILP) is a rare acute or subacute neuropathic syndrome affecting mainly motor lower limb. Multiple levels of lumbosacral plexus, nerve roots and their distal nerves can be affected. This is an idiopathic disorder that are clinically characterized by weakness; atrophy of the thigh muscles; and severe asymmetric leg pain. The another symptoms includes hypoesthesia; allodynia and autonomic dysfunction.[1]

This syndrome is usually monophasic, despite that the recovery is not complete, and the patients have sequelae. Have similar features between (ILP) and diabetic lumbosacral radiculoplexus neurophaty (DLRPN). The neurological characteristics are almost similar, although the pathological source is different.[2]

The pathogenesis and etiology is uncertain until now, but studies demonstrates alterations involves fiber degeneration, injury neuroma, focal thickening and microvascular ischemia.[3] No treatment has been proved until now. Actually is common to uses anti-inflammatory and immunomodulatory to reduces the symptomatology and brakes progression of the disease. To control another symptom like depression and anxiety, antidepressants can be useful. The physiotherapy can be applied to reduce movement limits and pain.[4]

Images granted by Hospital of Restauração, Recife-PE

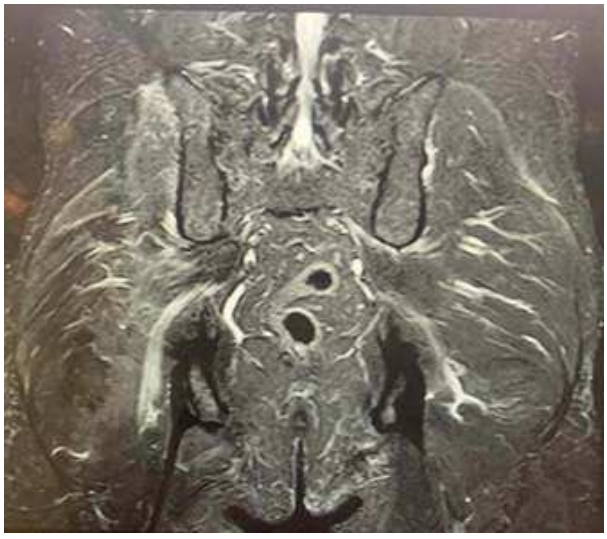

Image analysis

Magnetic resonance imaging (MRI) is the most important exam of neuroimaging in DLRPN and ILP. It is possible to analyze the anatomical component and correlate it with other findings from other exams, such as electroneuromyography, establishing an effective complementary exam.[5]



In MRI, it is possible to assess other probable etiologies for the symptomatic picture presented by the patient, identifying if there are tumors, traumatic damage, compression sites, and inflammation. It is also possible to analyze characteristics of each etiology, in addition to the extent of the lesion, its path, in addition to evaluating the appearance of the muscles and associated bone framework.[5]

A classic and common differential diagnosis is the clinical distinction between idiopathic lumbosacral plexopathy and radiculopathy due to disc degeneration, which is sometimes challenging, thus requiring imaging exams that can clarify.[6] In the image presented, there is no evidence of component lesions disc or degeneration by facet arthropathy.

The MRI is so useful to shows slightly to moderately increased T2 signal, gadolinium enhancement, or enlargement of the nerve roots, plexus, and peripheral nerves.[7]

In the image we observed revealed hyper signal in the L5 root on the right with Electroneuromyography compatible with ipsilateral root damage. This hyper signal denotes an idiopathic inflammation, since it has no evidence of demyelinating lesion; neuropraxia; axonotmesis; neurotmesis.

Neuropathy associated with paraproteins or paraneoplastics were also ruled out, as there were no findings of such etiologies in the image.

Furthermore, it is possible to see that there is no nerve compression that justifies the clinical picture and the evidenced inflammation. It is not possible to observe the presence of tumors, abscesses or traumatic lesions in the path of the nerve and its root or in the tissues adjacent to them.

T1-weighted sequences with 2-4 mm cut thickness and high resolution are one of the bests techniques for demonstrating the fascicular pattern of the normal nerve, and the anatomical structures around the nerve.[7]

Suppressed fat T2-weighted are very useful because have a sensitive detection of different nervous diseases. The administration of intravenous contrast agents can be utilized to facilitate the image analysis. This is very useful to verify an inflammatory pathology and neoplastic naturopathies.[7]

Robbins et. Al, 2016, identified different diffuse inflammatory plexopathies in their series, including heroin-associated vasculitic plexopathy and diabetic lumbosacral plexitis, multiple mononeuritis, hepatitis C-associated vasculitis, sarcoidosis, neuro-associated vasculitic plexitis, amyloidosis restricted to the plexus and others.[5]

In view of the careful analysis and investigation of the images, as well as the clinical picture and the history collected from the patient's anamnesis, it was postulated as an Idiopathic Plexopathy. The main differential diagnosis is Diabetic Plexopathy, which cannot be excluded by MRI, however the patient did not have diabetes, nor did he have a fluctuation in the glycemic rate.

However, it is worth noting that the role of MRI in this pathology is not to complete the diagnosis, as it is classified as idiopathic. It was essential to correlate with the patient's history, neurological examination and other tests (laboratory and electromyography).

Conclusion

The sequels and the clinical condition of the Lumbosacral plexopathy make that disease an important to be studied and researched for the next years. Nowadays does not have a consensus of the treatment and the diagnosis is not easy and not common. The neuroimaging exams, clinical history and physical examination are so helpful to find the diagnosis.

Artêmio José Araruna Dias
https://orcid.org/0000-0002-3565-0586
Júlio César Tavares Marques
https://orcid.org/0000-0002-4600-4731
Luís Felipe Gonçalves de Lima
https://orcid.org/0000-0002-0130-0625
Nilson Batista Lemos
https://orcid.org/0000-0002-2331-6871
Andrey Maia Silva Diniz
https://orcid.org/0000-0002-5572-7018
Otávio da Cunha Ferreira Neto
https://orcid.org/0000-0003-0517-0212
Keyvid dos Santos Pereira
https://orcid.org/0000-0003-1842-8956
Hildo Rocha Cirne de Azevedo Filho
https://orcid.org/0000-0002-1555-3578
Luiz Severo Bem Junior
https://orcid.org/0000-0002-0835-5995

References

1. Thaisetthawatkul P and Dyck PJ. **Treatment of diabetic and nondiabetic lumbosacral radiculoplexus neuropathy**. *Curr Treat Options Neurol* 2010;12(2):95-99 Doi: https://www.doi.org/ 10.1007/s11940-010-0059-8
2. Sander HW and Chokroverty S. **Diabetic amyotrophy: current concepts**. *Semin Neurol* 1996;16(2):173-178 Doi: https://www.doi.org/10.1055/s-2008-1040973
3. Kawamura N, Dyck PJ, Schmeichel AM, Engelstad JK, Low PA and Dyck PJ. **Inflammatory mediators in diabetic and non-diabetic lumbosacral radiculoplexus neuropathy.** *Acta Neuropathol* 2008;115(2):231-239 Doi: https://www.doi.org/10.1007/s00401-007-0326-2
4. Van Eijk J, Chan YC and Russell JW. **Immunotherapy for idiopathic lumbosacral plexopathy**. *Cochrane Database Syst Rev* 2013;12 Doi: https://www.doi.org/10.1002/14651858.CD009722.pub2
5. Robbins NM, Shah V, Benedetti N, Talbott JF, Chin CT and Douglas VC. **Magnetic resonance neurography in the diagnosis of neuropathies of the lumbosacral plexus: a pictorial review.** *Clin Imaging* 2016;40(6):1118-1130 Doi: https://www.doi.org/10.1016/j.clinimag.2016.07.003
6. McCormack EP, Alam M, Erickson NJ, Cherrick AA, Powell E and Sherman JH. **Use of MRI in diabetic lumbosacral radiculoplexus neuropathy: case report and review of the literature**. *Acta Neurochir (Wien)* 2018;160(11):2225-2227 Doi: https://www.doi.org/10.1007/s00701-018-3664-z
7. Filosto M, Pari E, Cotelli M, Todeschini A, Vielmi V, Rinaldi F, . . . Gasparotti R. **MR neurography in diagnosing nondiabetic lumbosacral radiculoplexus neuropathy**. *J Neuroimaging* 2013;23(4):543-544 Doi: https://www.doi.org/10.1111/jon.12039