

2021, 3(1):18-22 ▪ e-ISSN: 2674-7103

Jornal Memorial *da* Medicina

DOI: 10.37085/jmmv3.n1.2021.pp.18-22

Review
Surgical Medicine

Hemorrhagic angiomatous meningioma: what we know. Case report and review of the literature

Marcelo Palmares Oliveira e Silva **Vitor Palmares Oliveira e Silva** **Allan Victor Tavares da Silva** **Giovani Crestana Nogueira Lima** **Matheus Augusto Pinto Kitamura**

Universidade Federal de Pernambuco, Recife, Pernambuco, Brazil

Marcelo Palmares Oliveira e Silva
palmaresm12@hotmail.com

Edited by
Marcelo Moraes Valença

Keywords:
Angiomatous meningioma
Spontaneous hemorrhage
Neurosurgery
Intracranial tumor

Abstract

Meningiomas are the most common benign intracranial tumors and rarely present with spontaneous bleeding. We report on a case of hemorrhagic angiomatous meningioma that was treated surgically (the first case described in Brazil) and present a review of the literature. The patient was a 38-year-old female with progressive headache and vomiting. She also had a previous history of chronic headaches and refractory depression. Imaging studies showed a large left frontal extra-axial tumor, with intense contrast enhancement and hyperperfusion/hypervascularization. There was an extensive intratumoral and pericapsular hemorrhagic region, with dilation of the middle meningeal arteries and falx cerebri vessels. The lesion was compatible with hemorrhagic meningioma. The patient underwent bifrontal craniotomy and tumor devascularization, followed by total resection. Histopathological and immunohistochemical analyses led us to conclude that this was a case of angiomatous meningioma. Subsequently, the patient's headaches and depression improved. No residual or recurrent neoplastic lesion was observed during the follow-up.

Received: June 29, 2021
Accepted: June 30, 2021

© Copyright 2021

Introduction

Meningiomas are the commonest benign intracranial tumors[1]. Although these are richly vascularized lesions, spontaneous bleeding is rare[2] and such cases may become challenging. Few reports of angiomatous meningiomas with spontaneous hemorrhage have yet been published.

Here, we report on a case of angiomatous meningioma with an uncommon initial hemorrhagic presentation that was treated through surgical resection, and we present a specific review of the literature. So far, this is the first case of its type to be reported in Brazil.

Case report

The patient was a 38-year-old woman who was admitted to the emergency service with an incapacitating frontal pulsatile headache that she had for one day. This was accompanied by nausea and vomiting. Her neurological examination was normal. She had antecedents of chronic headache of the same pattern but of lower intensity, and history of hypothyroidism and treatment-resistant depression. She did not have any history of trauma or coagulopathy.

Magnetic resonance imaging (MRI) demonstrated the presence of a voluminous left frontal extra-axial solid tumor measuring 7.1 x 5.4 x 6.0 cm, with its base in contact with the frontal dura mater and falx cerebri, and with a significant mass effect and subcortical edema. This lesion presented intense contrast enhancement, hyperperfusion-hypervascularization and an extensive intratumoral and pericapsular hemorrhagic component. There was also increased vascularization of the left frontal bone plate. The findings were compatible with hemorrhagic meningioma (Figures 1A, 1B, and 1C).

Intracranial magnetic resonance angiography (MRA) demonstrated dilation of the middle meningeal arteries, which was greater on the left side. These participated in nutrition for the tumor, as did the falx cerebri vessels. The tumor was in contact

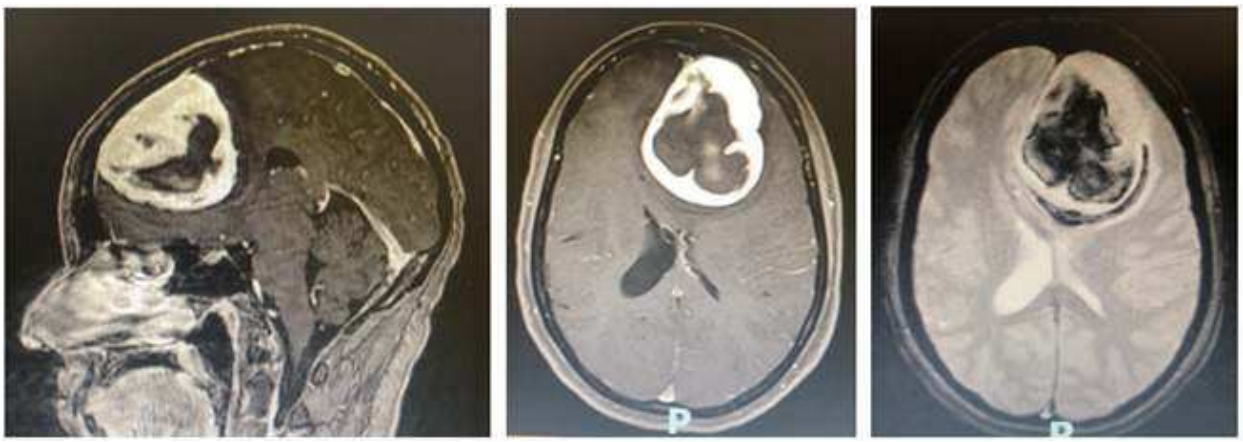

Figure 1: Left frontal tumor, isointense in T1 and T2-weighted MRI, with intense contrast enhancement, hyperperfusion, dural tail, peritumoral edema, and hemorrhage. 1A: MRI T1 sequence with contrast, in sagittal view. 1B: MRI T1 sequence with contrast, in axial view. 1C: MRI T2 sequence, in axial view.

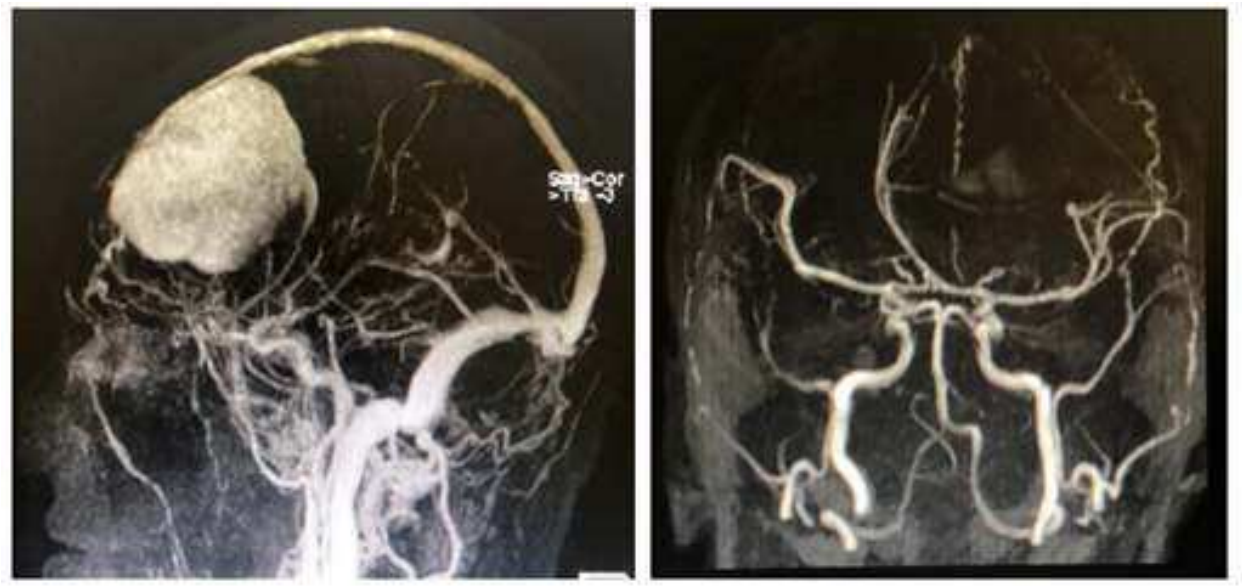

Figure 2: Intracranial magnetic resonance angiography (MRA) showing dilation of the middle meningeal artery and falx cerebri vessels. 2A: sagittal view. 2B: coronal view.

with the superior sagittal sinus, without invasion (Figures 2A and 2B).

The patent was admitted to the intensive care unit (ICU) and corticoid treatment was started. She underwent bifrontal craniotomy, with exposure of the superior sagittal sinus. The hematoma was drained and the tumor was devascularized. This was followed by complete resection of the tumor, curet tage, and coagulation of adjacent structures. There was no gross evidence of any remaining tumor or active bleeding. The postoperative period was free from complications. A cranial

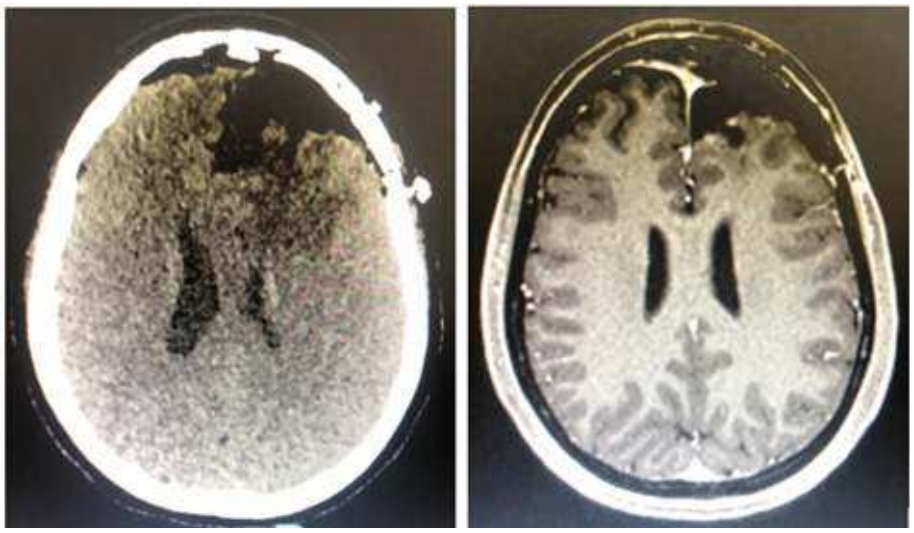

Figure 3: Postoperative images: 3A: Postoperative CT scan, in transversal view, showing total resection, wide surgical cavity and left frontal pneumocephalus, without hemorrhage. 3B: Control MRI, T1 sequence with contrast, in axial view, showing wide surgical cavity, with absence of residual or recurrent lesion.

CT scan showed that the postoperative appearance was satisfactory. Left frontal pneumocephalus was present (Figure 3A). The histopathological examination showed that this was a case of angiomatous meningioma, of WHO grade I. The sample was positive for epithelial membrane antigen, progesterone receptors and Ki-67 cell proliferation antigen.

During the patient's outpatient follow-up, her headache and depression improved. Through MRI done later on within the follow-up period, presence of residual or recurrent neoplastic lesion in the left frontal region could be ruled out (Figure 3B).

Discussion

Meningioma is the commonest primary tumor of the nervous system and accounts for 13% to 33.8% of all intracranial neoplasms.[3] The risk of developing this neoplasm increases with age and becomes significantly greater beyond the age of 65 years. It is twice as common in women and may be associated with progesterone receptors.[2] Its incidence is 4.4 cases per 100,000 people[3], and autopsy studies have shown prevalences of 2-3%.

Meningiomas are derived from capillary cells of the arachnoid and adhere to the dural surface. They are typically extra-axial lesions and can be separated from the adjacent cerebral tissue. The middle meningeal artery tends to be dilated as the artery that feeds the tumor.[4]

The symptoms caused depend on the site and size of the meningioma. In most cases, meningiomas give rise to symptoms such as headache, dizziness, convulsions, or gradual progression of neurological deficits.[1] It should be highlighted that 50-78% of cerebral tumors are accompanied by mental disorders and that 21% of patients with meningioma of the frontal lobe in the fourth decade of life only present psychiatric symptoms.[5]

Spontaneous bleeding is a rare complication of meningiomas, even though these are extremely vascularized tumors. The incidence of hemorrhagic meningiomas ranges from 0.5 to 2% in the literature.[2] The etiology that leads to the low rate of bleeding in meningiomas is uncertain. It is thought that this might occur through rupture of undifferentiated tumor and dural vessels because of rapid neoplastic growth, release of vasoactive substances, and necrosis.[6] The site of bleeding depends on the location of the tumor: subarachnoid hemorrhage occurs most commonly, followed by subdural hemorrhage.[1]

Angiomatous meningioma is a rare histological subtype of meningioma, according to the WHO classification. It generally presents a good prognosis and low recurrence rates.[7] It accounts for 2.1% of all meningiomas and is defined by predominance (greater than 50%) of the vascular component[8]. It is of notably benign nature and is placed in WHO grade 1, given its low cell multiplication rates, low Ki-67 levels and positivity for progesterone receptors. Despite its rich vascular structure, its bleeding rates are similar to those of other subtypes.[8]

The definitive diagnosis of angiomatous meningioma is made through histopathological evaluation. The location where it is most commonly found is the cerebral convexity (68.8%), followed by the falx cerebri (7.53%).[9] Typically, CT scans show mild hyperdensity. In MRI, the patterns most often reported are hypointensity in T1 and hyperintensity in T2.[4] Other common findings in cases of angiomatous meningioma include a ringlike signal (30.1%), peritumoral edema (87.1%), cystic formations (51.6%), and vascular voids (49.5%).[10]

After hemorrhagic meningioma has been diagnosed, a radical approach becomes necessary.[7] This consists of drainage of the hematoma and complete excision of the tumor. It is not always possible to achieve this final objective: the hemorrhage may worsen during the operation (seen in 63.8% of the cases), with the need for blood transfusion (14%).[9]

Conclusion

Spontaneous bleeding as the initial presentation of meningioma is rare, including in the angiomatous subtype. Careful analysis of radiological examinations may help in making differential diagnoses. Antecedents such as refractory depression, with or without accompanying chronic headaches, in patients may also raise suspicions of neoplasms of the frontal lobe.

Emptying of the hematoma, accompanied by total resection, is the treatment of choice for hemorrhagic meningiomas.

Marcelo Palmares Oliveira e Silva
https://orcid.org/0000-0002-5538-3753
Vítor Palmares Oliveira e Silva
https://orcid.org/0000-0003-4803-1255
Allan Victor Tavares da Silva.
https://orcid.org/0000-0002-0534-4406
Giovani Crestana Nogueira Lima:
https://orcid.org/0000-0001-9152-4827
Matheus Augusto Pinto Kitamura
https://orcid.org/0000-0003-2745-9068

References

1. Kin JH, Gwak HS, Hong EK, Bang CW, Lee SH, Yoo H (2015) **A Case of Benign Meningioma Presented with Subdural Hemorrhage**. *Brain Tumor Res Treat* 3(1):30-3.
2. Aloraidi A, Abbas M, Fallatah B, Alkhaibary A, Ahmed ME, Alassiri AH (2019) **Meningioma Presenting with Spontaneous Subdural Hematoma: A Report of Two Cases and Literature Review**, *World Neurosurg* 127:150-154.
3. Mawrin C, Perry A (2010) **Pathological classification and molecular genetics of meningiomas**. *J Neurooncol* 99:379–391.
4. Liu Z, Wang C, Wang H, Wang Y, Li JY, Liu Y (2013) **Clinical characteristics and treatment of angiomatous meningiomas: a report of 27 cases**. *Int J Clin Exp Pathol* 6 (4): 695-702.
5. Kiat SS, Adzman KAB, Msurg, Hieng AWS, FRACS (2019) **Large falcine meningioma presented as treatment-resistant depression: A case report**. *Med Malaysia* 74 (1): 87-9.
6. Wang HC, Wang BD, Chen MS, Li SW, Chen H, Xu W, Zhang JM (2016) **An Underlying Pathological Mechanism of Meningiomas with Intratumoral Hemorrhage: Undifferentiated Microvessels.** *World Neurosurg* 94: 319-27.
7. Modesti LM, Binet EF, Collins GH. (1976) **Meningiomas causing spontaneous intracranial hematomas.** *J. Neurosurg* 45: 437-41.
8. Hasselblatt M, Nolte KW, Paulus W (2004) **Angiomatous Meningioma: A Clinicopathologic Study of 38 Cases**. *Am J Surg Pathol* 28 (3): 390-3.
9. Nsir AB, Chabaane M, Krifa H, Jeme H, Hattab N (2010) **Intracranial angiomatous meningiomas: A 15-year, multicenter study**. *Clinical Neurology and Neurosurg* 149: 111-7.
10. Hua l, Luan S, Li H, Zhu H, Tang H, Liu H, Chen X, Bozinov O, Xie Q, Gong Y (2017) **Angiomatous Meningiomas Have a Very Benign Outcome Despite Frequent Peritumoral Edema at Onset.** *World Neurosurg* 108: 465-73.