

2021, 3(1):30-32 ▪ e-ISSN: 2674-7103

Jornal Memorial *da* Medicina

DOI: 10.37085/jmmv3.n1.2021.pp.30-32

Case Report

Lacunar lesion of the thalamus: a case report

Lesão lacuna no tálamo: relato de caso

Nataly Regina Fonseca Carvalho de Medeiros[1] Marcelo Andrade Valença[1] Elayne Cristina de Oliveira Ribeiro[1] Ana Carolina Barreira Roso[2] Ana Rita de Oliveira Souza da Silva[1] Mateus Marinho Silva de Souza[1] Talita Gabriele de Queiroz Plácido[3] Leandro Ferreira de Sá[4] José Gabriel da Silva[4] Fernanda Biatriz Silva Costa[4] Arthur Alves Rodrigues Alencar[5] Taianara Sampaio[6] Maiza de Oliveira Tenório[1] Larissa de Oliveira Beltrão[5] Débora Aline Oliveira Portela de Carvalho[7], Danielle Almeida Santos Paes Ferreira Marcelo Moraes Valença[1]

[1]Universidade Federal de Pernambuco, Recife, Pernambuco, Brazil.
[2]Hospital da Restauração, Recife, Pernambuco, Brazil.
[3]Uninassau, Recife, Pernambuco, Brazil
[4]Universidade Federal de Pernambuco, Campus Acadêmico do Agreste, Caruaru, Pernambuco, Brazil
[5]Faculdade Pernambucana de Saúde – Instituto Materno Infantil de Pernambuco, Recife, Pernambuco, Brazil
[6]Unifacisa, Campina Grande, Paraíba, Brazil
[7]Universidade Católica de Pernambuco, Recife, Pernambuco, Brazil.

✉ Nataly Regina Fonseca Carvalho de Medeiros
natalyreg@gmail.com

Edited by
Juliana Ramos Andrade

Keywords:
Stroke
Lacunar
Thalamus
Diagnostic
Imaging

Palavras-chave:
Acidente Vascular Cerebral Lacunar
Doenças Talâmicas
Diagnóstico por Imagem

Abstract

In this article, the authors present a computed tomography (CT) image scan of the brain of a 72-year-old patient who, upon waking, noticed numbness in the left hemiface, hemithronchus, and upper limb. Sensorimotor syndromes are commonly related to vascular infarction of inferolateral artery (ILA) territory, also known as thalamogeniculate pedicle. Usually this pain disturbance happens in right thalamic infarcts having a delayed onset, however, it might be acutely presented.

Resumo

Neste artigo, os autores apresentam uma tomografia computadorizada (TC) do cérebro de um paciente de 72 anos que, ao acordar, notou dormência na hemiface esquerda, hemitronco e membro superior. As síndromes sensório-motoras são comumente relacionadas ao território do infarto vascular da artéria inferolateral (ILA), também conhecido como pedículo talamogeniculado. Normalmente, esse distúrbio de dor ocorre em infartos talâmicos direitos, tendo um início tardio, no entanto, pode ser apresentado de forma aguda.

Received: June 11, 2021
Accepted: June 17, 2021

© Copyright 2021

Introduction

The vascular supply of the thalamus's nuclei is composed of four arteries (*i.e.*, tuberothalamic, inferolateral, paramedian, and posterior choroidal vessels). These arteries can receive different anatomic names.[1] The arteries branches and their tributaries may individually vary in number and location.[2] When small subcortical lesions within 15 mm are occluded by a penetrating artery from a large cerebral artery, we may call it as lacunar infarctions. Those may cause lacunar syndromes.[3] In this article, the authors present a computed tomography (CT) image scan of the brain of a patient with a lacunar lesion of the thalamus.

Case report

A 72-year-old woman presented, upon waking numbness in the left hemiface, hemitrunk, and upper limb. On physical examination, tactile hypoesthesia was detected in the left hemibody with mild left central facial paralysis. CT shows a lacunar lesion in the right ventroposterolateral thalamus (Figure 1).

Comment

Sensorimotor syndromes are commonly related to vascular infarction of inferolateral artery (ILA) territory, also known as thalamogeniculate pedicle (Figure 2). This artery emerges from the P2 segment of the Posterior Cerebral Artery (PCA). The principal inferolateral branches of ILA vascular territory respond to the supply of the ventral posterior thalamic nucleus complex.[4] This infarction area can be related to all modalities of sensorial loss with variable extent besides motor deficits, as presented in this case. The thalamic syndrome can also be followed by central poststroke pain, which is presented in 80% of cases.[5] Usually, this pain disturbance happens in right thalamic infarcts having a delayed onset, however, it might be acutely presented.

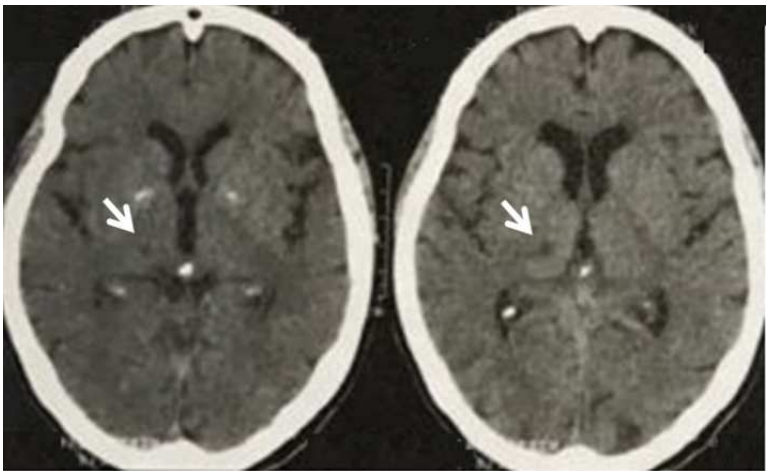

Figure 1. Computed tomography (CT). Small inferolateral artery territory infarction in the right thalamus (arrows), presented as a lacunar hypodense spot. It corresponds to the ventral posterior thalamic nuclei complex.

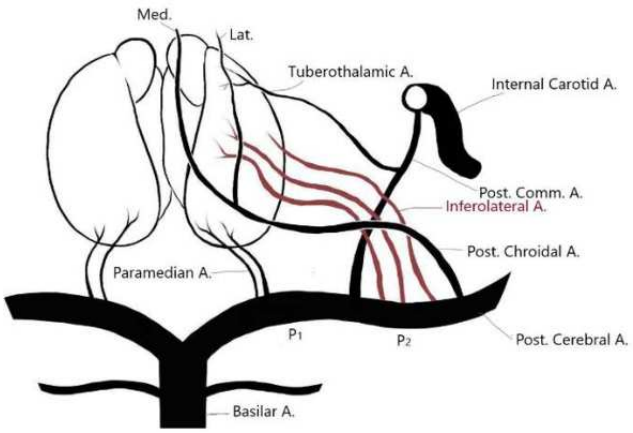

Figure 2. Schematic image of thalamus irrigation.

Nataly Regina Fonseca Carvalho de Medeiros
https://orcid.org/0000-0003-4415-395X
Marcelo Andrade Valença
https://orcid.org/0000-0002-0824-0928
Elayne Cristina de Oliveira Ribeiro
https://orcid.org/0000-0002-5243-3356
Ana Carolina Barreira Roso
https://orcid.org/0000-0001-7835-8270
Ana Rita de Oliveira Souza da Silva
https://orcid.org/0000-0002-9055-8790
Mateus Marinho Silva de Souza
https://orcid.org/0000-0003-1558-8524
Talita Gabriele de Queiroz Plácido
https://orcid.org/0000-0003-3860-6561
Leandro Ferreira de Sá
https://orcid.org/0000-0001-5391-7304
José Gabriel da Silva
https://orcid.org/
Fernanda Biatriz Silva Costa
https://orcid.org/0000-0002-3061-0737
Arthur Alves Rodrigues Alencar
https://orcid.org/0000-0002-6204-4530
Taianara Sampaio
https://orcid.org/0000-0002-7419-2485
Maiza de Oliveira Tenório
http://orcid.org/0000-0002-0968-0423
Larissa de Oliveira Beltrão
https://orcid.org/0000-0001-9341-1914
Danielle Almeida Santos Paes Ferreira
https://orcid.org/0000-0001-6357-531X
Marcelo Moraes Valença
https://orcid.org/0000-0003-0678-3782

References

1. J. D. Schmahmann. **Vascular Syndromes of the Thalamus.** *Stroke* 2003;34(9):2264-2278 Doi:10.1161/01.str.0000087786.38997.9e
2. P. Castaigne, F. Lhermitte, A. Buge, R. Escourolle, J. J. Hauw and O. Lyon-Caen. **Paramedian thalamic and midbrain infarct: clinical and neuropathological study**. *Ann Neurol* 1981;10(2):127-148 Doi:10.1002/ana.410100204
3. P. Venkataraman, P. Tadi and F. Lui. **Lacunar Syndromes. StatPearls**. Treasure Island (FL): StatPearls Publishing Copyright© 2021, StatPearls Publishing LLC.; 2021
4. J. Bogousslavsky, F. Regli and G. Assal. **The syndrome of unilateral tuberothalamic artery territory infarction**. *Stroke* 1986;17(3):434-441 Doi:10.1161/01.str.17.3.434
5. J. Dejerine. **Le syndrome thalamique**. *Rev. Neurol.* (Paris) 1906;12:521-532